

Tanta University

Cardiology MD Degree (Policy 2013)

Faculty of Medicine


Number of Questions: One Case (200 Marks)

Department of Cardiology

Time Allowed: One and half Hours

November 13<sup>th</sup>, 2021

Commentary Case – MD



A 41-year-old female sought medical care due to severe dyspnea. The patient had had acute rheumatic disease in childhood. During evolution, she developed mitral stenosis. The symptoms became incapacitating and she underwent mitral valvuloplasty at 36 years. She progressed well for a few years until dyspnea recurred and she was once again submitted to hospital, at 41 years, when she underwent mitral valvuloplasty (03/16/2005).

After the intervention, she had dyspnea on great exertion for about three months, when it progressed and started to be triggered by middle, and finally by mild exertion, and at three days before hospitalization (10/10/2005), it had become present even at rest. The patient attributed the recent worsening to current medication discontinuation: Captopril 25 mg, Furosemide 80 mg, digoxin 0.25 mg and warfarin 2.5 mg daily.

Physical examination (10/10/2005) showed the patient was in good general health, dyspneic, with a marked increase in jugular venous pressure, pulse rate of 92 bpm, blood pressure of 100/60 mmHg. Lung examination was normal. Cardiac auscultation showed irregular rhythm without additional heart sounds. Systolic murmur (+1/+4) was diagnosed in the mitral valve area. There were no alterations at the abdominal examination, but slight edema of the lower limbs.

Laboratory tests (10/10/2005) showed hemoglobin 11.7 g/dL, hematocrit 35%, WBC, 3,900/ mm<sup>3</sup>, platelets, 129,000 /mm<sup>3</sup>, creatinine 1.3 mg/dL, urea 31 mg/dL, sodium 135 mEq/L, potassium 3.6 mEq/L, INR 1.19.

The electrocardiogram (10/10/2005) showed frequency of 90 bpm, atrial fibrillation, low voltage QRS complex, undetermined QRS axis in the frontal plane and presence of intraventricular stimulus conduction disturbance of the right branch type and decreased left ventricular potential, suggesting right ventricular overload.

The patient was admitted for treatment. She remained in the emergency unit for five days and was admitted (10/15/2005). She received Furosemide 120 mg intravenously, Enalapril 40mg, Digoxin 0.25 mg, Hydrochlorothiazide 50 mg and Enoxaparin 120 mg daily by subcutaneous route, as well as dobutamine 10 µg/kg/min intravenously.

At hospitalization she had hypotension, increased edema and creatinine elevation. After three days, the patient developed anuria, anasarca and finally shock despite the use of 15 µg/kg/min of dobutamine.

The laboratory tests (10/20/2005) showed creatinine 3.2 mg/dL and then 5.9 mg/dL, Urea 75 mg/dL and, during evolution, 115 mg/dL.

At physical examination (10/20/2005) the patient was in poor general condition, with blood pressure of 80/50 mmHg, heart rate 90 bpm, crackles in both lungs, arrhythmic heart sounds (atrial fibrillation), systolic murmur +1/+4 in the mitral area, ascites and edema +4/+4.

The electrocardiogram (10/20/2005) showed atrial fibrillation, heart rate of 100 bpm, low QRS voltage, intraventricular conduction disturbance of the right bundle branch block type stimulus, decreased left ventricular strength.

The echocardiogram (10/21/2005) showed normal left ventricle, dilated and hypokinetic right ventricle, mitral valve calcification, commissural fusion, moderate stenosis and moderate tricuspid regurgitation.

---

1- What is your impression?

2- What is your evaluation to the management strategy?

3- What is the cause of last deterioration?

4- What is your final diagnosis?

Good luck



Tanta University

Cardiology MD Degree (Policy 2013)

Faculty of Medicine


Number of Questions: 29 (Total 260 Marks)

Department of Cardiology

Time Allowed : 3 Hours

November 6<sup>th</sup>, 2021

Final Exam, Second Paper



**First: Short Questions (Each Question 20 marks):**

1. Management of premature ventricular beats in athletes.
2. Novel oral anticoagulations (NOACS) in end stage renal disease.
3. Common arrhythmias in Fallot and how to manage.
4. Novel hypocholesterolaemic drugs.
5. Risk stratification and therapy of patients with asymptomatic pre-excitation.
6. Post-COVID syndrome.

**Second: Ultrashort Questions (Each Question 10 marks):**

1. Colchicine and the heart.
2. Management AF patients post intracranial haemorrhage.
3. Intervention in atrioventricular septal defect.
4. Exercise in young individuals/athletes with anomalous origins of coronary arteries.
5. Plasma aldosterone concentration to plasma renin activity (PAC/PRA) ratio.
6. Assessment of hypertension-mediated organ damage.
7. Cardiorenal syndrome type 3.
8. Anti-hypertensive drugs for lactating mother.
9. NOACs therapy in thrombocytopenia.
10. CARNEY SYNDROME.

**Third: MCQ (Each Question 2 marks):**

1. All the following are feature of isolated systolic hypertension except:
  - A. Age of onset > 55 years.
  - B. Due to arterial stiffness.
  - C. Progress is slow variable.
  - D. Leads to heart failure/stroke.
  
2. One of the following is true regarding the prevalence of HTN:
  - A. HTN is more prevalent in high –income countries.
  - B. HTN is more prevalent in low –income countries.
  - C. The prevalence of HTN in adults is around 30 – 45%.
  - D. HTN prevalence of >50% in people aged >60 years.
  
3. Most common clinical manifestation of left atrial myxoma is:
  - A. Embolism.
  - B. Arthralgia.
  - C. Syncope.
  - D. Haemoptysis.
  
4. Commonest malignant tumour of heart is:
  - A. Angiosarcoma.
  - B. Fibrosarcoma.
  - C. Malignant lymphoma.
  - D. Neurogenic sarcoma.
  
5. In which cyanotic congenital heart disease both aortic root and pulmonary trunk are likely to be normal or reduced?
  - A. Fallot's tetralogy.
  - B. Truncus arteriosus.
  - C. Eisenmenger's reaction.
  - D. Ebstein's anomaly.
  
6. Which of the following facts about identification of VF is true?
  - A. A peripheral pulse that is both weak and irregular indicates VF.
  - B. A sudden drop in cardiac output to 50% of normal indicates VF.
  - C. Artifact signals displayed on the monitor can look like VF.
  - D. Turning the signal amplitude ("gain") to zero can enhance the VF signal.

**7. Commonest cause of death in PDA is:**

- A. Heart failure.
- B. Rupture of ductal aneurysm.
- C. Hypertensive aneurysm of pulmonary track.
- D. Infective endocarditis.

**8. Which is the commonest associated condition with coarctation of aorta?**

- A. PDA.
- B. Common ventricle.
- C. ASD.
- D. Hypoplastic left heart syndromes.

**9. According to risk assessment, a 40 years old male patient with FBS=90mg%, TC=190 mg%, not smoker and BP=190/110 mmHg is considered.**

- A. A very high risk.
- B. High risk.
- C. Moderate risk.
- D. Low risk.

**10. Left atrial appendage (LAA) occlusion to reduce the thromboembolic risk in male patients with AF and a CHA<sub>2</sub>DS<sub>2</sub>VASc score  $\geq 2$  undergoing valve surgery.**

- A. Is recommended.
- B. Should be considered.
- C. May be considered.
- D. Is not recommended.

**Fourth: Problem Solving MCQ (Each Problem 5 marks):**

**First Problem (5 marks):**

A 58-year-old woman in good health presents for evaluation. She is concerned about cardiovascular risk because her father sustained a myocardial infarction at age 70.

- **All of the following statements about heart disease in women are true EXCEPT:**
- A. Cardiovascular disease is the leading cause of death in Women.
  - B. In recent decades, age-adjusted cardiovascular mortality in the United States has increased in women while it has declined in men.
  - C. Coronary heart disease presents approximately 10 years later in women than in men.
  - D. Cardiovascular disease is twice as common in women with diabetes compared with nondiabetics.
  - E. Hormone replacement therapy with estrogen does not reduce the risk of cardiac events in postmenopausal women.

**Second Problem (5 marks):**

A 40-year-old female patient who takes oral anticoagulation (OAC) is going for surgery.

- **OAC bridging is recommended in all the following situations EXCEPT:**
- A. Mechanical prosthetic heart valve replacement.
  - B. Atrial fibrillation with CHA<sub>2</sub>DS<sub>2</sub>VASc score  $\geq 3$ .
  - C. Atrial fibrillation with severe aortic stenosis.
  - D. Acute thrombotic stroke in the previous month.



**Third Problem (5 marks):**

A 62-year-old man presents with syncope while working in his yard (standing position). He did not have any prodrome and sustained a head bruise. He does not report any recent chest discomfort or dyspnea. He has a history of myocardial infarction 5 years previously, and he takes aspirin, metoprolol, lisinopril, thiazide diuretic, and atorvastatin. His electrocardiogram shows inferior Q waves, but no ischemic ST-T abnormalities and no conduction abnormality. His echocardiogram shows inferior hypokinesis with an overall LVEF of 45%. His troponin I level is normal.

➤ **What is the next best step?**

- A. Coronary angiography.
- B. Admit for telemetry monitoring then discharge home next day if no arrhythmia is seen, with a diagnosis of vasovagal syncope.
- C. Place a 30 - day event monitor.
- D. Place an implantable loop recorder.
- E. Tilt table testing.
- F. Admit for telemetry monitoring and perform an electrophysiologic (EP) study.

**Fourth Problem (5 marks):**

A 65-year-old male patient who underwent TAVI 6 months ago. He is not hypertensive, nor diabetic, and is currently asymptomatic, his examination reveals: no peripheral edema, clear lungs and variable heart sounds. ECG shows atrial fibrillation.

➤ **Routine oral anticoagulation (OAC) use in this patient:**

- A. Is recommended.
- B. Should be considered.
- C. May be considered.
- D. Not recommended.

Good luck

Tanta University

Cardiology MD Degree (Policy 2013)

Faculty of Medicine


Number of Questions: 28 (Total 260 Marks)

Department of Cardiology

Time Allowed : 3 Hours

October 30<sup>th</sup>, 2021

Final Exam, First Paper



**First: Short Questions (Each Question 20 marks):**

1. Non-structural prosthetic valve dysfunction.
2. Invasive assessment of right side heart haemodynamics.
3. De-escalation of antiplatelets after PCI.
4. Clearance of cardio-vascular medications during hemodialysis.
5. Tricuspid valve intervention.
6. PCI in cancer patients.

**Second: Ultrashort Questions (Each Question 10 marks):**

1. Novel treatment of amyloidosis.
2. Enumerate cardiac causes of elevated level of natriuretic peptides.
3. Phenotypic clustering of dilated cardiomyopathy patients.
4. Post transcatheter aortic valve replacement (TAVR) heart failure.
5. Enumerate role of cardiac biomarkers in COVID-19.
6. Enumerate predictors of complications of aortic intramural hematoma.
7. Precautions for usage of SGL2 inhibitors in heart failure.
8. Imaging of aortic root diseases.
9. ECMO indications and limitations
10. Assessment and targeting euvolemia inpatient with heart failure.



**Third: MCQ (Each Question 2 marks):**

**1. All of the following is correct about Hyperkalaemia except:**

- A. Hyperkalaemia is defined as serum potassium >5 mmol/L.
- B. Can be classified as mild (>5.0 to <6 mmol/L), moderate (6 to 6.5 mmol/L), or severe (>6.5 mmol/L).
- C. It is associated with an increased risk of hospitalization and death.
- D. Can be associated with the administration of RAAS inhibitors, CKD and increased absorption.

**2. The best two-dimensional (2-D) and Doppler echocardiographic finding to differentiate restrictive cardiomyopathy from constrictive pericarditis would be to evaluate:**

- A. Pulmonary venous flow pattern.
- B. Atrial size.
- C. Early diastolic mitral annular velocity.
- D. Mitral inflow pattern.
- E. Inferior vena cava dilatation.

**3. Which of the following is true about the treatment of IE?**

- A- When enterococci resistant to both penicillin G and vancomycin cause endocarditis, no medical therapy is reliably effective.
- B- Celazolin may be used to treat enterococcal endocarditis.
- C- Oral agents such as fluconazole and itraconazole are the treatment of choice for fungal endocarditis.
- D- High dose IV penicillin alone is effective in curing enterococcal endocarditis caused by penicillin-susceptible enterococci.

**4. All of the following are echo criteria for severe AR except:**

- A. Dense continuous wave Doppler of the regurgitant jet.
- B. Vena contracta width =5 mm.
- C. Pressure half time <200ms.
- D. Regurgitant volume=60ml/beat.

5. Time course from myocardial ischemia to necrosis can be prolonged by all of the following EXCEPT:
- A. Increased collateral flow.
  - B. Increased myocardial oxygen consumption.
  - C. Preconditioning.
  - D. Timely reperfusion.
6. Each of the following statements concerning the utility of cardiac biomarkers in patients with acute coronary syndromes is correct EXCEPT:
- A. Levels of C-reactive protein (CRP) are greatly elevated in patients with an acute coronary syndrome (ACS) compared with patients with stable coronary disease.
  - B. CRP and cardiac-specific troponin levels offer complementary information in the prognosis of patients with ACS.
  - C. In patients with unstable angina, an elevated myeloperoxidase level is associated with increased risk of death.
  - D. Patients with elevated levels of B-type natriuretic peptide have a twofold to threefold increased risk of adverse events.
  - E. Patients with non-ST-elevation MI and elevated white blood cell (WBC) counts have similar mortality rates as those with normal WBC counts.
7. Expected clinical manifestations of amyloidosis of the cardiovascular system include which of the following?
- A. Constrictive pericarditis.
  - B. High-output heart failure.
  - C. Orthostatic hypotension.
  - D. ECG voltage criteria for left ventricular hypertrophy.
  - E. Electrical alternans.

**8. Surgical reconstruction (in distinction to replacement) of the mitral valve is likely to be successful in each of the following patients EXCEPT:**

- A. A 37-year-old man with mitral valve prolapse.
- B. A 62-year-old man with severe mitral regurgitation due to annular dilatation after myocardial infarction.
- C. A 48-year-old woman with mitral regurgitation due to ruptured chordae tendineae with active infective endocarditis.
- D. A 70-year-old woman with rheumatic heart disease, calcified mitral valve with deformed leaflets, and combined mitral stenosis and regurgitation.
- E. A 23-year-old man with a congenitally cleft mitral valve.

**9. All of the following are correct regarding Omecamtiv Mecarbil except:**

- A. Increase the systolic ejection time and increase LV pressure.
- B. Produced dose-dependent increases in systolic ejection time.
- C. Does not increase intracellular cAMP or calcium.
- D. Is a Cardiac Myosin Activator
- E. Used to treat HFrEF patients.

**10. Each of the following statements regarding endomyocardial fibrosis (EMF) is correct EXCEPT:**

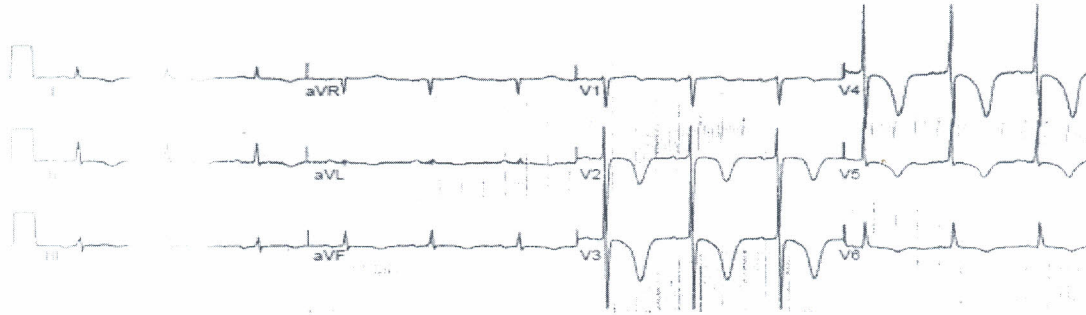
- A. This condition is characteristically found in tropical and subtropical Africa.
- B. It is predominantly a disease of children and young adults.
- C. Involvement of the mitral valve apparatus typically results in mitral stenosis.
- D. EMF involves the left ventricle, alone or in combination with the right ventricle, in 90% of patients.
- E. Echocardiographic features include increased endocardial reflectivity, fibrotic obliteration of the apex, atrial enlargement, and pericardial effusion.



**Fourth: Problem Solving MCQ (Total 20 marks):**

**First Problem (5 marks):**

A 62-year-old previously healthy man is brought to the emergency department because of severe headache and dizziness. He has no chest pain or dyspnea. He takes no medications. His blood pressure is 186/98 mm Hg; his heart rate is 56 beats/min and regular. The presenting ECG is shown:



➤ **Which of the following actions is appropriate?**

- A. Initiate antiplatelet therapy with aspirin and Clopidogrel.
- B. Initiate antithrombotic therapy with heparin.
- C. Initiate anti-ischemic therapy with intravenous nitroglycerin and a beta blocker.
- D. Obtain a head computed tomographic scan.
- E. Proceed directly to cardiac catheterization if ST-segment/T wave abnormalities fail to quickly normalize with anti-ischemic therapy.

**Second Problem (5 marks):**

A 60-year-old hypertensive man presents with tearing back pain. MRI confirms the presence of a descending thoracic dissection originating beyond the left subclavian artery.

➤ **Appropriate initial treatment includes:**

- A. Immediate surgery to replace the descending aorta.
- B. Intravenous nitroprusside followed by immediate surgery.
- C. Intravenous nitroprusside alone; surgery for persistent pain, or for involvement of renal or mesenteric arteries.
- D. Intravenous beta-blockade and nitroprusside; surgery for persistent pain, or for involvement of renal or mesenteric arteries.

**Third Problem (5 marks):**

A 78-year-old man calls 911 because he has sudden-onset chest pain. On EMS arrival he has a BP of 120/80 mmHg and a heart rate of 80 beats per minute. His lungs are clear to auscultation and he has a left ventricular (LV) S4 noted. ECG done on the field confirms an anterior MI with ST elevation from V1 to V4. He is given an aspirin and a sublingual nitroglycerin and transfer is initiated. Within 5 minutes while en route his BP is noted to be 60 mmHg and a saline bolus is initiated. Cardiovascular examination is unchanged and no murmurs are noted.

- Which of the following scenarios may likely explain his observed hemodynamic deterioration?
- A. Hypotension resulting from bleeding due to administration of aspirin
  - B. Right ventricular (RV) infarction
  - C. Anaphylaxis reaction from aspirin
  - D. Recent exposure to a phosphodiesterase 5 inhibitor
  - E. Massive pulmonary embolism

**Fourth Problem (5 marks):**

A 55 year-old female patient, who had mitral valve replacement 4 years ago, is now complaining of SOB, lower limbs edema, and abdominal pain. Her echo shows severe TR, dilated RV /RA, and TAPSE = 0.7 cm.

- One of the following maybe considered:
- A. Mechanical tricuspid valve replacement.
  - B. Bioprosthetic tricuspid valve replacement.
  - C. Loop potassium sparing diuretic and digitalis.
  - D. Trans-catheter tricuspid valve treatment.

Good luck