

All questions must be answered
Time Allowed : 3 hours
Total marks : 100

1-A 62 year old man presents to the emergency department with a one week history of left lower quadrant abdominal pain and diarrhea. He complains of increased pain ,nausea vomiting and fever . He has had two prior episodes of similar condition that resolved with antibiotic treatment alone. He has no cardiac or pulmonary risk factors. On examination his blood pressure is 140/80 heart rate 110 p/min and temperature 38 0c his abdomen is soft and mildly distended with left lower quadrant tenderness to palpation. There is no evidence of generalized peritonitis. His WBC count is 20.000.

40

- a-What is the most likely diagnosis
- b-How could you prove the diagnosis.
- c- What are the complication of this condition

2- Surgical site infection, causes , prophylaxis and management

30

3- The differential diagnosis of chronic leg ulcers and treatment of venous ulcers.

30

Good Luck

سوف تعقد امتحانات الشفوى والاكلينيكى بالقسم يوم

23 اكتوبر باذن الله الساعة الثامنة صباحا



Tanta University
Faculty of Medicine
General Surgery Department

General Surgery Written Exam.

Ophthalmology


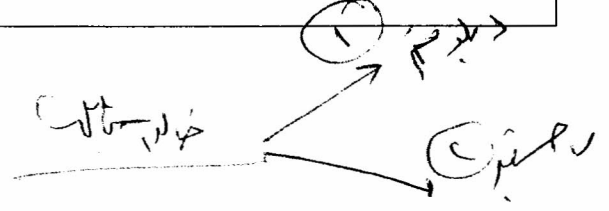
21TH October 2013

All questions must be answered Number of Questions :3 Time Allowed : 3 hours Total marks : 100

٣٥ 1- Complications of blood transfusion.

٢٥ 2- Manifestations of orbital fractures

٢٠ 3- Discuss the differential diagnosis of ulcers on the upper face



Good Luck

امتحان الشفوى والاكلينيكي السبت 26/ 10 الساعة الثامنة صباحا ان شاء الله



Tanta University
Faculty of Medicine
General Surgery Department

General Surgery
ENT
21TH October 2013

All questions must be answered Number of Questions :3 Time Allowed : 3 hours Total marks : 100

1----- A20-year-old man involved in a car crash sustained severe injuries to the chest, abdomen, and lower extremities. He requires increasing concentration of oxygen to maintain his PO_2 .



- What is your approach for assessment
- What is the investigations needed
- What is the pathologic changes suspected in this patient



2- Differential diagnosis of solitary thyroid nodule

ع. ١١٤/١١/٤
د. محمد عبد الله



3- What are the manifestations of midface fractures and management of nasal fractures

Good Luck

امتحان الشفوى والاكلينيكى السبت 10/26 الساعة الثامنة صباحا ان شاء الله



All questions must be answered Number of Questions 4 Time Allowed : 3 hours Total marks : 100

✓

1- A 20-year-old man involved in a car crash sustained severe injuries to the chest, abdomen, and lower extremities. He requires increasing concentration of oxygen to maintain his PO₂.

25

- a- What is your approach for assessment?
- b- What are the investigations needed?
- c- What are the pathologic changes suspected in this patient?

2- Causes and management of surgical site infections

25

✓

3- The differential diagnosis of inguinoscrotal mass

25

4. Discuss the clinical picture and investigations of intestinal obstruction

25

Good Luck

امتحان الشفوى والاكلينيكى الاحد 10/ 27 الساعة الثامنة صباحا ان شاء الله



1 - A 20-year-old man involved in a car crash sustained severe injuries to the chest, abdomen, and lower extremities. He requires increasing concentration of oxygen to maintain his PO₂.

- a- What is your approach for assessment ?
- b- What are the investigations needed ?
- c- What are the pathologic changes suspected in this patient ?

2- What are the differential diagnosis of right iliac fossa mass?

3- Discuss the early post operative abdominal surgery complications

4- Management of the intestinal obstruction in pregnant women

Good Luck

امتحان الشفوى والاكلينيكى الاحد 27 / 10 الساعة الثامنة صباحا ان شاء الله



Tanta University
Faculty of Medicine
General Surgery Department

General Surgery Written Exam.

Orthopedic

21TH October 2013

All questions must be answered Number of Questions 4 Time Allowed : 3 hours Total marks : 100

1- A 20-year-old man involved in a car crash sustained severe injuries to the chest, abdomen, and lower extremities. He requires increasing concentration of oxygen to maintain his PO₂.

30

- a- What is your approach for assessment? *ATL*
b- What are the investigations needed?
c- What are the pathologic changes suspected in this patient? *↵*

- 2- Differential diagnosis of swollen lower limb
3- ---What are the risk factors of deep vein thrombosis
4- Manifestations and management of ulnar nerve injury

20

25

25

Good Luck

امتحان الشفوي والاكلينيكي الخميس 24/ 10 الساعة الثامنة صباحا ان شاء الله

Tanta University
Faculty of Medicine
Surgery Department

Date: 12/10/2013

M.Sc. and Diploma radiology , Oncology

All questions to be answered:

1- Discuss manifestation and management of deep vein thrombosis.

20

2- Differential diagnosis of midline neck swelling.

20

Good Luck

1. / CA ...

Handwritten notes in Arabic: "ع. د. د. ٢٠١٣" and "النجاح هو ..."

Tanta University
Faculty of Medicine
Surgery Department

Date: 12/10/2013

M.Sc. and Diploma radiology , Oncology

All questions to be answered:

- 1- Discuss manifestation and management of deep vein thrombosis.**
- 2- Differential diagnosis of midline neck swelling.**

Good Luck

امتنان، استاذ مساعد، كلية الطب، جامعة طنطا