
Mansoura Veterinary Medical Journal

REPRODUCTIVE TOXICITY OF CHLORPYRIFOS, CYPERMETHRIN AND THEIR INTERACTION IN MALE ALBINO RATS

Asmaa M. ELnamaky, Amal A. Halawa, Mamdouh M. Abouelimged

Forensic Medicine and Toxicology Department, Fac. Vet. Med., Mansoura University, Egypt.

ABSTRACT

The present work was designed to investigate the reproductive toxicity induced by oral administration of chlorpyrifos (CPF), cypermethrin (CYP) and their combination in adult male albino rats. Forty mature male albino rats were separated into four groups (10 each), the first group was used as control, while second, third and fourth groups received orally 1/20 LD50 of CPF (10 mg/kg b.wt), 1/20 LD50 of CYP (17.22 mg/kg b.wt) and 1/40 LD50 of CPF plus 1/40 LD50 of CYP (5 mg/kg b.wt CPF plus 8.61 mg/kg b.wt CYP) respectively for 26 days. The results revealed that exposure to CPF and/or CYP induced a significant decrease in the reproductive organs weight. Moreover, a significant decrease in spermatid picture (sperm cell concentration and viability) was observed with high percent of sperm abnormalities. Serum levels of testosterone and pituitary gonadotropins (FSH and LH) have been declined significantly in all treated groups. Significant elevations were observed in malondialdehyde and nitric oxide concentrations, while antioxidant enzymes superoxide dismutase and glutathione-S-transferase activities were decreased significantly as a result of induced oxidative stress. A significant drop in prostatic acid phosphatase activity was observed. Additionally, the results showed some histopathological alterations in the reproductive organs as well as neurological lesions in brain and pituitary glands. In conclusion, CPF and CYP induce deleterious effects on reproductive efficiency of male rats which reflect more obvious impacts when both combined.

INTRODUCTION

Pesticides are group of chemicals that have been used for eradication of harmful pests in agricultural and other domestic applications to improve crops yield for enhancing food production and controlling disease vectors. Although the global need of pesticides due to their benefits in general, they induce serious environmental pollution and health hazards under continuous uncontrolled application (Fang et al., 2013; Ikpeme et al., 2016). Pesticides are considered potent toxicants for reproductive health in humans and animals which may induce male infertility (Ezeji et al., 2015).

Chlorpyrifos (CPF) is an effective broad spectrum organophosphate insecticide that is

commonly used in agricultural, domestic and industrial purposes (Heikel et al., 2014). It is moderately hazardous class II insecticide (WHO, 2010). The oral LD₅₀ of CPF in adult male rats is 200 mg/kg b.wt (Savithri et al. 2016). CPF elicits its toxicity through inhibition of acetylcholinesterase enzyme and accumulation of acetylcholine in the synapses leading to hyper excitability of the cholinergic receptors. Also, CPF can exert its toxic effect via non-cholinergic pathways such as, inducing of oxidative stress (Ogutcu et al., 2008; Heikal et al., 2013). CPF is a potent toxicant affecting male reproductive system via modulating weight of reproductive organs as well as sperm parameters (count, motility, viability and morphology). Also, CPF is considered an endocrine disruptor through its effect on reproductive hormones. Also, CPF

induces testicular damage which manifested by alteration of testicular histoarchitecture in response to oxidative stress induced with repeated exposure which may affect male fertility (Joshi et al., 2007; Kenfack et al., 2015; Savithiri et al., 2016; Alaa-ELdin et al., 2017).

Cypermethrin (CYP) is one of effective type II synthetic pyrethroids, is widely used to control various pests in agricultural and other domestic purposes, such as pests of cotton, fruit and vegetable crops (Sharma et al., 2014). CYP has α - cyano group at the α -carbon of ester linkage, thus Type II pyrethroids is more potent neurotoxic than type I. Its oral LD₅₀ is 344.45 mg/kg b.wt in adult male rats (Hummdi et al., 2016). CYP acts mainly by delaying the closure (prolonged opening time) of voltage-gated sodium channels (VGSCs) and thus increases the Na⁺ influx, which consequently depolarizes the cell membrane resulting in over excitation (Soderlund, 2012). CYP can elicit a wide range of reproductive toxic alterations in weight of reproductive organs, reduction in functional sperms as well as in levels of sex hormones and changes in testicular histology through induced oxidative stress (Joshi et al., 2011; Noaishi et al., 2012; Sharma et al., 2014; Alaa-ELdin et al., 2017).

Previous studies proved that the irreversible inhibition of esterases by organophosphates leads to inhibition of activity of carboxylase enzymes responsible for hydrolysis of pyrethroids and consequently slowing down its biotransformation and excretion, thus, synergistic effect between organophosphates and pyrethroids may be expected (Wielgomas and Krechniak, 2007). It was found that CPF and CYP elicit potent damage when used in combination rather than separate use on the reproductive function of exposed species including significant reduction in sperm parameters with significant increase in sperm head abnormalities. Furthermore,

serum levels of sex hormones were significantly declined (Zhou et al., 2011; Noaishi et al., 2012; Ikpeme, 2016; Alaa-ELdin et al., 2017).

The main goal of the current work is to investigate the individual and joint effect of CPF and CYP on the genital system of adult male albino rats.

MATERIALS AND METHODS

1. Chemicals

Ictafos 48% EC (Chlorpyrifos 48% EC) was purchased from Bagera Chemical Azwand Estres Co. India.

Ustaad 10% EC (Cypermethrin 10% EC) was purchased from United Phosphorous Limited Co. Mumbai, India.

2. Experimental animals and design:

Forty mature male albino rats (250 \pm 20 g with 4.5 months old), were purchased from The Unit of Experimental Animals, Faculty of Veterinary Medicine, Zagazig University, Egypt. The animals were apparently clinically healthy. They were placed in plastic cages with wood shavings as bedding and kept under controlled conditions (23 \pm 1 °C, 12 h light /dark cycle). Rats were supplied with standard laboratory pelleted diet and water ad libitum. After 2 weeks accommodation period, animals were distributed into four groups (n=10): The first group used as control and received 0.5 ml distilled water orally. The second, third and fourth groups received 10 mg/kg b.wt (1/20 LD₅₀) CPF, 17.22 mg/kg b.wt (1/20 LD₅₀) CYP and 5 mg/kg b.wt CPF + 8.61 mg/kg b.wt CYP (1/40 LD₅₀ for each), respectively every other day for 26 days. Rats were kept under daily observation until the end of experimental period.

3. Sample collection and tissue preparation:

Animals were sacrificed at the end of the experimental period then fresh blood was immediately collected via cardiac puncture (Ekaluo et al., 2013). Clear sera were separated carefully and stored at -20°C until estimation of sex hormones and acid phosphatase enzyme. Testes were homogenized in ice cold phosphate puffer saline (PBS), PH 7.4, and centrifuged at 3000 rpm for 15 minutes at 4°C. The supernatant was collected carefully and stored at -20°C until evaluation of oxidative stress according to (Ferdandez-Botran et al. 2002).

Reproductive organs (testes, epididymis and reproductive glands) were dissected out, washed in cold ice saline and weighted for calculation of index weight (I.W). I.W was calculated according to Bearden and Fuquay (1980).

$$\text{Index weight (I.W)} = (\text{organ weight} / \text{body weight}) \times 100$$

Sperm count was evaluated according to Beadern and Fuquay (1980) using a modified formula:

$$\text{Sperm concentration/ml} = \frac{N}{80} \times 400 \times 200 \times 10 \times 1000$$

Live and dead sperms were expressed as a percent and sperm abnormalities were determined according to Ikpeme et al. (2007).

Serum samples were analyzed for reproductive hormones by solid phase enzyme-linked immunosorbent technique (ELISA) according to the instructions of manufacture. Testosterone was estimated according to Chen et al. (1991), LH was analyzed according to Knobil (1980) and FSH was analyzed according to Johnson et al. (1983).

Tissue homogenates were analyzed using enzymatic colorimetric method according to the manufacturer's instructions. MDA, an indicator for lipid peroxidation, was measured according to Satoh (1978), Superoxide dismutase activity was determined according to Nishikimi et al. (1972) and glutathione-S-

transferase activity was determined according to Habig and Pabst (1974). Nitric oxide concentration was estimated according to Montgomery and Dymock (1961). While serum acid phosphatase was analyzed according to Kind and King (1954).

4. Histopathological examination:

Specimens from reproductive organs (testes, epididymis, genital glands), brain and pituitary gland were collected and fixed in neutral buffered formalin 10% for histopathological examination. Sections of 5 micron thickness were prepared from collected specimens, stained by (H&E) and then examined by ordinary microscope according to Suvarna et al. (2012).

5. Statistical Analysis:

Data were analyzed statistically by using statistical software program (SPSS for Windows, version 20, USA).

RESULTS

Results revealed a significant decrease in index weight of testes, epididymis and genital glands in all treated groups compared to the control one. Results are shown in Table (1).

Regarding sperm parameters, our results elicited a significant reduction in sperm count and viability of all exposed groups compared to control group with additional significant reduction in CPF plus CYP treated group. CYP and CPF treated groups showed significant variation in sperm viability. Results are shown in Table (2).

Our data showed a significant elevation in the percent of sperm abnormalities in all exposed groups compared to control group with additional significant elevation in CPF plus CYP treated group. Results are shown in Table (2). Types of sperm abnormalities are presented in Table (3).

Table 1: Index weight of reproductive organs of treated rats with CPF, CYP and their combination (Mean \pm SE), (n=10):

| Groups | Testicular Index weight | Epididymal Index weight | Reproductive glands Index weight |
|--|--------------------------------|---------------------------------|----------------------------------|
| Control | 0.540 ^a \pm 0.009 | 0.207 ^a \pm 0.0124 | 0.794 ^a \pm 0.061 |
| CPF (1/20 LD ₅₀) | 0.448 ^b \pm 0.012 | 0.167 ^b \pm 0.0122 | 0.551 ^b \pm 0.047 |
| CYP (1/20 LD ₅₀) | 0.465 ^b \pm 0.018 | 0.174 ^b \pm 0.006 | 0.531 ^b \pm 0.027 |
| CPF+CYP (1 /40 LD ₅₀ of each) | 0.446 ^b \pm 0.019 | 0.153 ^b \pm 0.011 | 0.476 ^b \pm 0.046 |

The means in the same column having the same superscript were not significantly different ($P < 0.05$).

Table 2: Sperm count, viability and abnormalities of treated rats with CPF, CYP and their combination (Mean \pm SE), (n=10):

| Groups | Sperm count (10 ⁶ / ml) | Sperm viability (%) | Sperm abnormalities (%) |
|--|------------------------------------|--------------------------------|--------------------------------|
| Control | 245.00 ^a \pm 13.84 | 88.90 ^a \pm 2.316 | 7.30 ^c \pm 0.831 |
| CPF (1/20 LD ₅₀) | 200.00 ^b \pm 10.54 | 72.70 ^b \pm 3.062 | 50.10 ^b \pm 3.433 |
| CYP (1/20 LD ₅₀) | 190.00 ^b \pm 17.95 | 49.90 ^c \pm 2.311 | 54.00 ^b \pm 3.365 |
| CPF+CYP (1 /40 LD ₅₀ of each) | 140.00 ^c \pm 12.47 | 32.40 ^d \pm 3.091 | 66.90 ^a \pm 1.797 |

The means in the same column having the same superscript were not significantly different ($P < 0.05$).

Table 3: Types of Sperm abnormalities of treated rats with CPF, CYP and their combination:

| | Detached head | Coiled head | Abnormal head | Detached tail | Bent tail | Coiled tail |
|--|---------------|-------------|---------------|---------------|-----------|-------------|
| CPF (1/20 LD ₅₀) | 22 % | 5 % | 4% | 24 % | 26 % | 19 % |
| CYP (1/20 LD ₅₀) | 19 % | 2 % | 4 % | 24 % | 27 % | 24 % |
| CPF+CYP (1 /40 of LD ₅₀ each) | 25 % | 3 % | 5 % | 25 % | 26 % | 16 % |

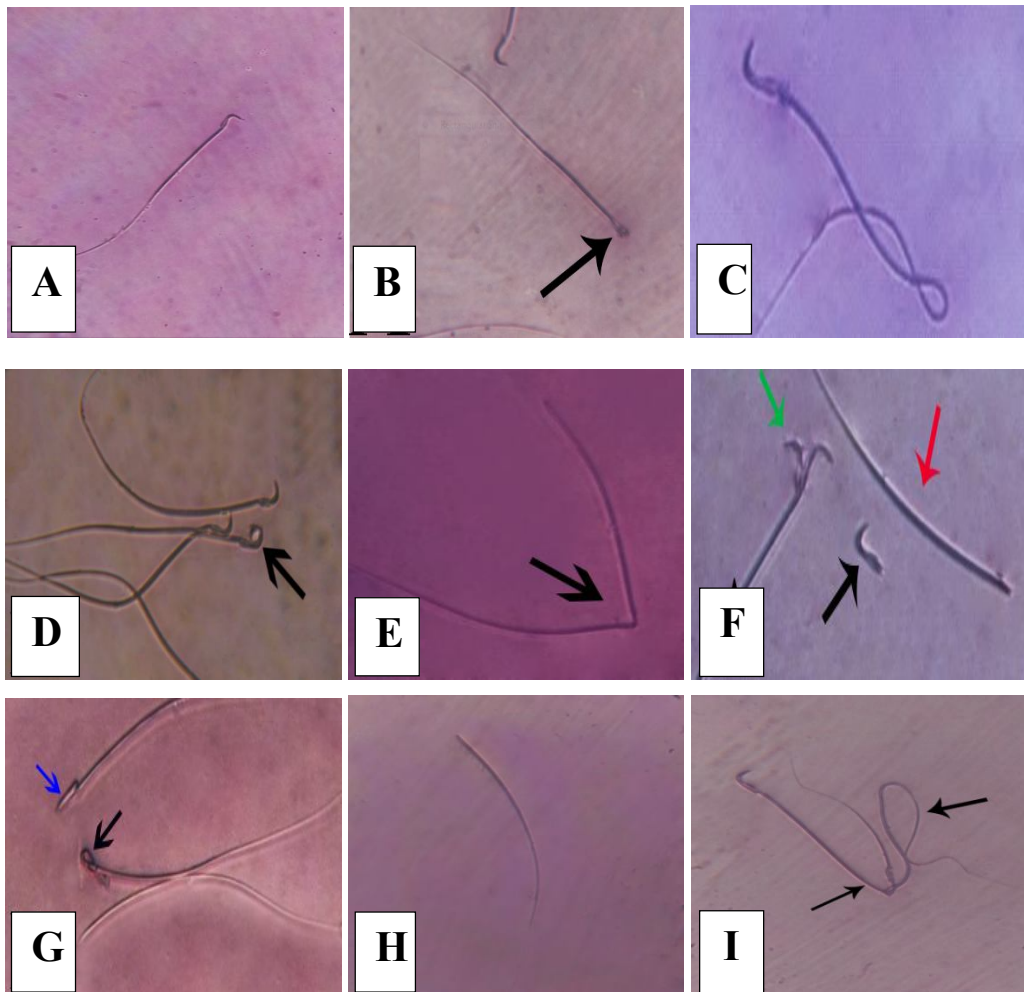


Fig. 1: Sperm abnormalities in treated rats with CPF, CYP and their interaction (A) Normal sperm (control) (B) Abnormal head (C) Coiled tail (D) Coiled hock (E) Broken tail (F) Double head (green arrow), Detached head (black arrow) and Detached tail (red arrow) (G) Coiled head (black arrow) and banana-shaped head (blue arrow) (H) Detached tail (I) Bent tail.

Concerning reproductive hormones, the current results revealed a significant decline in the serum levels of testosterone hormone, FSH and LH in all treated groups compared to

control group with additional significant decline in their levels in CPF plus CYP treated group (1/40 LD₅₀ each) compared to other treated groups. Results are shown in Table (4).

Table 4: Serum levels of reproductive hormones of treated rats with CPF, CYP and their combination (Mean \pm SE), (n=10):

| Groups | Testosterone (ng/ml) | FSH (mIU/ml) | LH (mIU/ml) |
|--|--------------------------------|--------------------------------|--------------------------------|
| Control | 2.033 ^a \pm 0.162 | 0.104 ^a \pm 0.009 | 0.278 ^a \pm 0.007 |
| CPF (1/20 LD ₅₀) | 0.966 ^b \pm 0.094 | 0.060 ^b \pm 0.006 | 0.225 ^b \pm 0.008 |
| CYP (1/20 LD ₅₀) | 1.012 ^b \pm 0.097 | 0.072 ^b \pm 0.006 | 0.229 ^b \pm 0.009 |
| CPF+CYP (1 /40 LD ₅₀ of each) | 0.523 ^c \pm 0.036 | 0.026 ^c \pm 0.003 | 0.189 ^c \pm 0.006 |

The means in the same column having the same superscript were not significantly different ($P < 0.05$).

The results showed a significant increase in the level of malondialdehyde (MDA) of all treated groups compared to control group. A significant elevation was observed in the level of MDA in CPF plus CYP treated group compared to other treated groups.

The results revealed a significant reduction in the activity of SOD enzyme of all exposed groups compared to the control one. Additional significant reduction was observed in the activity of SOD enzyme in CPF plus CYP exposed group compared to other exposed groups.

Our results revealed a significant decrease in GST enzyme activity in all administered groups compared to control group with significant variations among all treated groups.

The results indicated a significant increase in the level of NO in all treated groups compared to control group. Highest increase in testicular NO level was observed in CPF plus CYP treated group. Results are shown in Table (5).

Table 5: Testicular oxidative stress of treated rats with CPF, CYP and their combination (Mean \pm SE), (n=10):

| Groups | Lipid Peroxide (MDA) (nmol/g tissue) | Superoxide dismutase (SOD) (U/g tissue) | Glutathione-S-Transferase (GST) (U/g tissue) | Nitric Oxide (NO) (μ mol/L) |
|--|--------------------------------------|---|--|----------------------------------|
| Control | 3.80 ^c \pm 0.388 | 139.10 ^a \pm 5.295 | 382.30 ^a \pm 4.333 | 24.40 ^c \pm 1.024 |
| CPF (1/20 LD ₅₀) | 7.50 ^b \pm 0.500 | 114.60 ^b \pm 3.933 | 285.00 ^c \pm 6.439 | 33.90 ^b \pm 2.141 |
| CYP (1/20 LD ₅₀) | 8.60 ^b \pm 0.476 | 108.70 ^b \pm 3.330 | 305.20 ^b \pm 8.673 | 35.30 ^b \pm 2.409 |
| CPF+ CYP (1/40 LD ₅₀ of each) | 10.90 ^a \pm 0.657 | 94.50 ^c \pm 6.127 | 280.60 ^c \pm 7.254 | 45.20 ^a \pm 3.402 |

The means in the same column having the same superscript were not significantly different ($P < 0.05$).

The results evoked a significant increase in the activity of total acid phosphatase enzyme with a significant decrease in the activity of Prostatic acid phosphatase enzyme in all exposed groups compared to control

group. A significant decrease in the activity of Prostatic acid phosphatase enzyme was observed in CPF plus CYP treated group compared to other treated groups Results are shown in Table (6).

Table 6: Total and prostatic acid phosphatase activity of treated rats with CPF, CYP and their combination (Mean \pm SE), (n=10):

| Groups | Total acid phosphatase (U/L) | Prostatic acid phosphatase (U/L) |
|--|--------------------------------|----------------------------------|
| Control | 77.50 ^b \pm 3.697 | 36.90 ^a \pm 0.737 |
| CPF (1/20 LD ₅₀) | 80.50 ^a \pm 2.986 | 30.50 ^b \pm 1.759 |
| CYP (1/20 LD ₅₀) | 83.30 ^a \pm 2.344 | 26.80 ^b \pm 2.009 |
| CPF+ CYP (1/40 LD ₅₀ of each) | 88.20 ^a \pm 2.444 | 11.80 ^c \pm 1.041 |

The means in the same row having the same superscript were not significantly different ($P \leq 0.05$).

Histological findings:

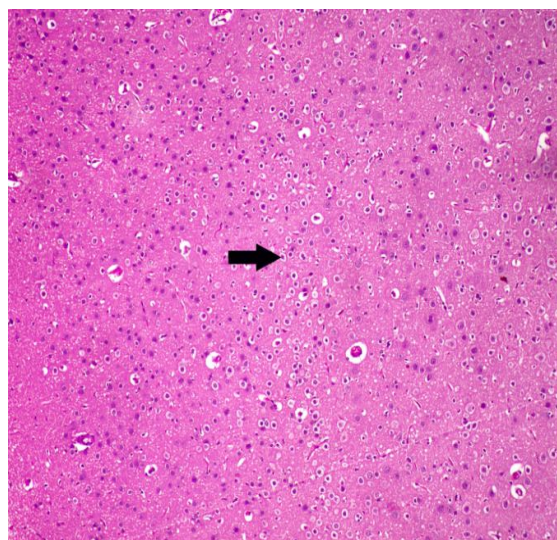


Fig. 2: Section from brain of rats received orally chlorpyrifos (1/20 LD₅₀) for 26 days, showing chromatolysis of neurons (loss of Nissl granules containing neurotransmitters) (arrow). (HE, 100X)

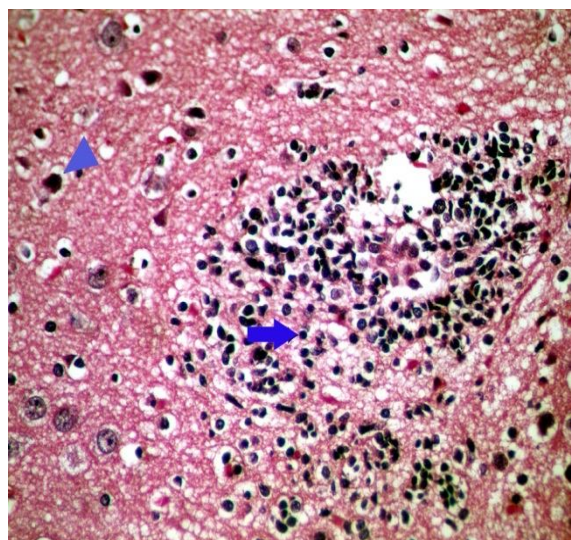


Fig. 3: Section from brain of rats received orally CPF+CYP (1/40 LD₅₀ of each) for 26 days, showing gliosis (arrow) and neuronal necrosis (arrow head). (HE, 400X)

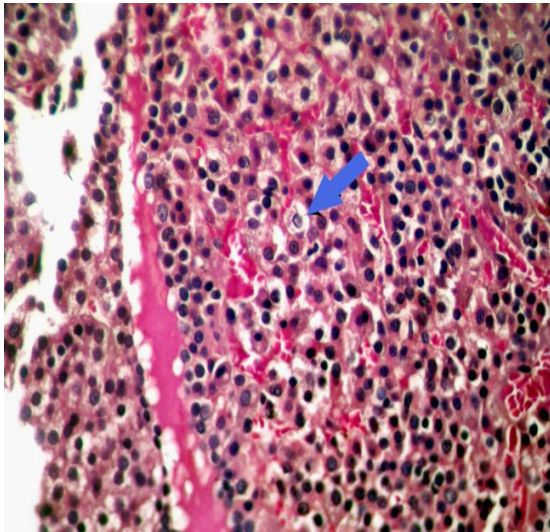


Fig. 4: Section from pituitary gland of rats received orally cypermethrin (1/20 LD₅₀) for 26 days, showing degeneration of epithelial cells of pars distalis (arrow). (HE, 400X)

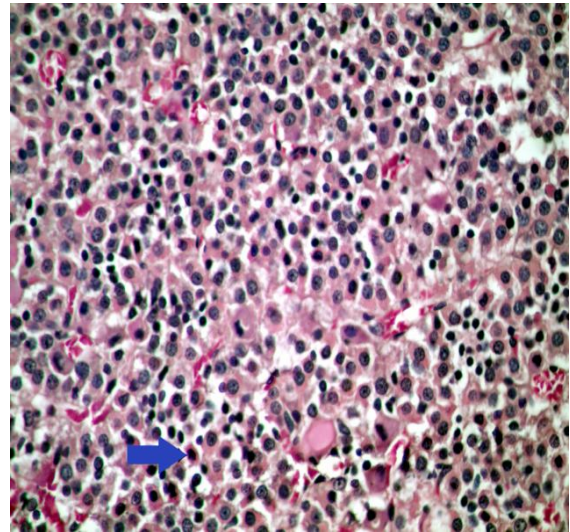


Fig. 5: Section from pituitary gland of rats received orally CPF+CYP (1 /40 LD₅₀ of each) for 26 days, showing apoptosis of epithelial cells of pars distalis (arrow). (HE, 400X)

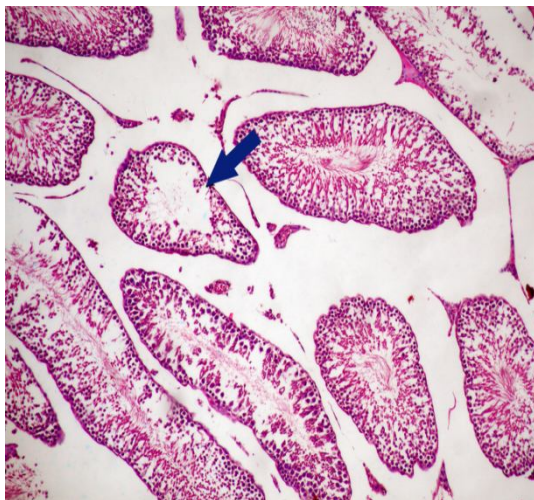


Fig. 6: Section from testis of rats received orally cypermethrin (1/20 LD₅₀) for 26 days, showing degenerative changes of spermatogenic epithelium lining seminiferous tubules (arrow). (HE, 100X)

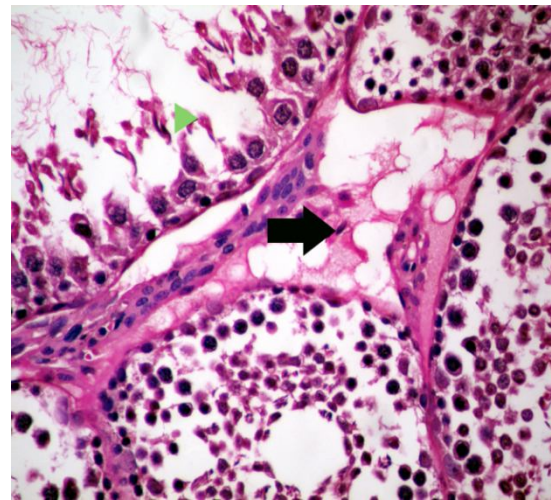


Fig. 7: Section from testis of rats received orally CPF+CYP (1 /40 LD₅₀ of each) for 26 days, showing degeneration of Sertoli cells in seminiferous tubules (arrow head) with edema of interstitial capillaris (arrow). (HE, 400X)

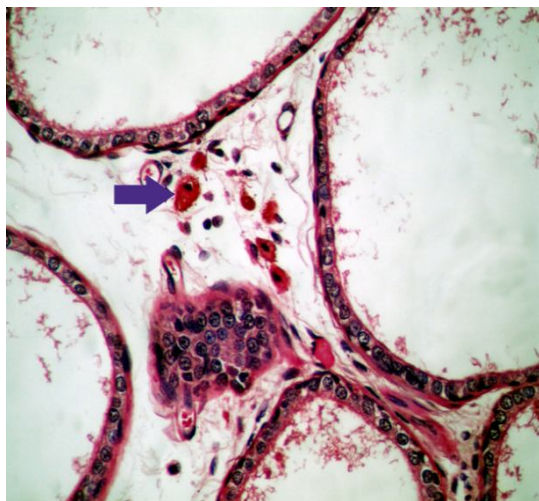


Fig. 8: Section from epididymis of rats received orally CPF+CYP (1/40 LD₅₀ of each) for 26 days, showing histiocytic infiltrates (eosinophilic infiltration) in interstitial tissue and its lumen slightly have spermatozoa (arrow). (HE, 400X)

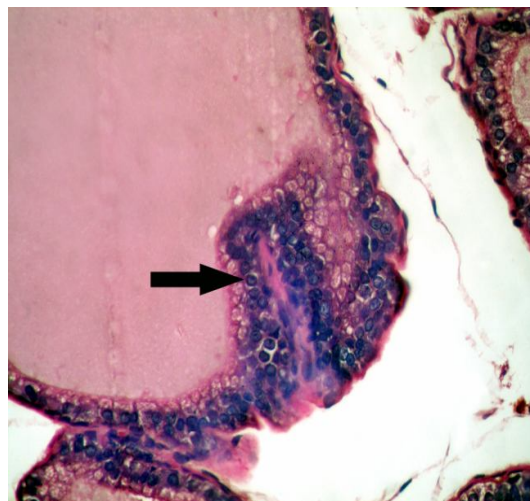


Fig. 9: Section from seminal vesicles of rats received orally CPF+CYP (1/40 LD₅₀ of each) for 26 days, showing hyperplasia of epithelial lining with normal eosinophilic secretion in the lumen (arrow). (HE, 400X)

DISCUSSION

Extensive use of environmental chemicals including pesticides without control is considered a potent hazard for serious environmental pollution and health threats including interference with male reproductive system which may impair male fertility (Sharma et al., 2014; Ikpeme et al., 2016). CPF and CYP can elicit variable degrees of reproductive toxicity in exposed animals (Elbetieha et al. 2001; Joshi et al 2007, Joshi et, 2011; Fang et al., 2013; Sharma et al., 2014; Sai et al., 2014). Not only exposure to pesticides as a mixture can generally produce significant synergistic toxicity on target organisms, but also they are considered hazardous to non-target species in most cases (Ben Abdallah et al. 2010; Zhou et al., 2011). Only few studies examined joined reproductive toxicity of CPF and CYP Zhou et al. (2011); Maharajan et al. (2015); Ikpeme et al. (2016)

and Alaa-Eldin et al. (2017) who demonstrated that the reproductive toxicity in case of co-exposure to both chemicals was more pronounced than single administration of each. The current work is applied to assess the individual and joint effects of CPF and CYP on the reproductive system of adult male albino rats.

The present results revealed that exposure to CPF or CYP evoked significant reduction in reproductive organs index weight (testes, epididymis and genital glands). Change in organs weight is one of valuable indicators for reproductive toxicity (Sai et al., 2014). CPF and CYP exert their suppressive effects on testicular function that may lead to infertility through direct cytotoxic effect on testes through depression of steroid biosynthesis in Leydig cells (EL-Kashoury and Tag EL-Din, 2010; Joshi et al., 2011). Reduced serum levels of sex hormones (testosterone, FSH and LH) after CPF and CYP exposure due to direct

effect at hypothalamic or pituitary through inhibition of hypothalamo-hypophyseal axis resulting in low level of gonadotropins (FSH and LH) that affect testosterone synthesis and secretion (Ikpeme et al. 2016; Alaa-Eldin et al., 2017) that is illustrated by severe neurological lesions in brain and pituitary gland induced by co-exposure, as both compounds are potent neurotoxicants, as CPF is considered neuroendocrine disruptor that inhibits acetylcholinesterase, resulting in accumulation of acetylcholine at the cholinergic receptors in the nervous systems. Also, Induction of oxidative stress is another way for CPF to exert its toxic effects (Umosem et al., 2012). CYP is a lipophilic compound thus can cross the blood–brain barrier and secreted in blood circulation inducing alterations in plasma membrane, increasing lipid peroxidation (Khan, 2009). Anti-androgenic activity of CYP is through inhibition of testicular enzymes necessary for testosterone biosynthesis, such as 17 β -hydroxysteroid dehydrogenase and glucose-6-phosphate dehydrogenase (Joshi et al., 2011), competitive interaction with androgen receptors and sex hormone-binding globulin (SHBG) causing disturbance in endocrine system by inhibitory effect on hypothalamo-pituitary-testis axis (Fang et al., 2013) or inhibition of dihydrotestosterone (DHT)-induced androgen receptor through direct effect on the testes that affect the androgen biosynthesis in Leydig cells (Ahmed et al. (2012). The decline in the epididymal and accessory genital glands weight could be linked to that of the testis as they are androgen-sensitive organs, depend on testosterone level. Testosterone is essential for their growth and function, so that a reduction in their weights may reflect a reduction in androgens bioavailability and production (Zidan., 2009; Heikel et al., 2014). Accumulation of CYP in testes induces oxidative stress responsible for decreasing weight of reproductive organs

(Sharma and Singh, 2010) that is confirmed by degenerative changes of spermatogenic epithelium lining seminiferous tubules. CPF and CYP are considered as endocrine disruptors, decrease serum testosterone level as well as FSH and LH levels. Steroidogenesis process is regulated by hypothalamo-hypophyseal axis, that might be disrupted by toxic effect of each compound which lead to suppression of spermatogenesis as well as development of seminiferous tubule, so the inhibition of spermatogenesis is resulting in reduction of sperm count (Elbetieha et al. 2001; EL-Kashoury and Tag EL-Din, 2010; Dutta and Sahu, 2013; Sharma et al., 2014; Alaa-Eldin et al., 2017). Co-exposure to CPF and CYP caused excess reduction in reproductive organs weight with low level of sex hormones (testosterone, FSH and LH) than each pesticide alone that confirmed by histological alteration that showed degeneration of Sertoli cells in seminiferous tubules with edema of interstitial capillaries. Also, epididymis showed eosinophilic infiltration in interstitial tissue and its lumen slightly has spermatozoa as well as hyperplasia of epithelial lining seminal vesicles with normal eosinophilic secretion in the lumen. Organophosphate pesticides are able to cross the blood–testicular barrier and cause the degeneration of the spermatogenic epithelium and Leydig cells (Uzun et al., 2009). These findings are in coordination with (Mosbah et al., 2014; Maharajan et al., 2015; Ikpeme et al., 2016; Alaa-Eldin et al., 2017).

The current results showed a significant reduction in sperm parameters (count and viability) with marked increase in percent of sperm abnormalities after CPF or CYP, while co-exposure showed more significant alteration in sperm parameters. The action of CPF and CYP as endocrine disruptors, decreased serum levels of sex hormones (testosterone, FSH and LH) which resulted in suppression of

spermatogenesis and development of seminiferous tubule leading to reduction of sperm count (Sharma et al., 2014; Alaa-Eldin et al., 2017). Accumulation of CPF and CYP in the reproductive organs may accelerate oxidative stress and produce high levels of reactive oxygen species (ROS) resulting in decrease cell viability and deterioration in sperm parameters through interference with differentiation of spermatozoa and DNA damage that may be associated with male infertility (Yao and Wang, 2008; Al-Hamdani and Yajurvedi, 2010; Sharma et al., 2014).

Oxidative stress is the disturbance in balance between the formation of free radicals (redox) and the ability of cells to protect itself against induced damage. It occurs due to either over production of ROS or impairment capacity to repair oxidative damage through insufficient antioxidant defense mechanism. Damage persuaded by ROS includes deleterious changes in cellular macroelements such as membrane lipids, proteins or DNA. The damage may inhibit cell function through changes in intracellular calcium or intracellular PH, and eventually leading to cell death (Heikel et al., 2014; Savithri et al., 2016). Testicular damage caused by CPF and CYP is originated by the formation of free radicals that is an evident for degradation of total lipids and generation of lipid peroxide that expressed in high level of testicular malondialdehyde (MDA). MDA is one of the chief oxidative products of polyunsaturated fatty acids peroxidation, thus increased MDA level is valuable indicator of lipid peroxidation leads to membrane damage and impairment of cellular function (Atessahin et al. 2005; Kalender et al., 2012; Sharma et al., 2014). Results showed insufficient antioxidant defense mechanism such as testicular SOD and GST after CPF and/ or CYP exposure might reflect cellular oxidative stress. SOD is considered the first effective way of defense against

deleterious effects of ROS in the cell which is responsible for protection of cells. Both enzymatic and non-enzymatic defense mechanisms are employed by the living organisms to scavenge the cellular damage, resulting from interactions between cellular constituents and the ROS. The oxidative stress induced by CPF and CYP may have depleted cellular SOD level caused by reduction in its biosynthesis or elevation its degradation or inactivation (Wang et al. 2009; Shittu et al., 2012; Sharma et al., 2014; Savithri et al., 2016). GST is one of phase-II detoxifying enzyme that catalyzes the conjugation of a variety of electrophilic substrates to thiol group of GSH, producing less toxic metabolites (Mansour and Mossa, 2010). Previous studies reported a significant decrease in the GST activity with exposure to CPF and CYP (Khan and Kour, 2007; Kalender et al., 2012; Sharma et al., 2014).

The results showed a significant increase in the level of Nitric Oxide (NO) in treated rats especially at co-exposure to CPF and CYP. Nitric Oxide is synthesized from an essential amino acid L-arginine produced by various cells in different organs under control of iso-enzymes nitric oxide synthetase (NOS) (Oyeyipo et al., 2015). Nitric Oxide is one of ROS which is contributed in various signaling mechanisms in many tissues and plays a major role in the control of gonadal functions. Very low amount of NO in semen has a role in regulation of normal sperm functions, whereas high levels of NO cause deleterious effect on sperm function and viability. NO donor molecules inhibited GnRH which is responsible for LH release from the anterior pituitary so, inhibition of NOS facilitates LH release from pituitary gland (Singh and Chaturvedi , 2013). Previous studies demonstrated that CPF and CYP increased the nitric oxide concentration (Wang et al., 2009; ELelaimy et al., 2012). A significant decline

in Acid phosphatase activity was found in testicular tissue of CPF and/or CYP treated rats reflecting inhibition in testicular function and indicating suppression of spermatogenesis (Dutta and Sahu, 2013). Acid phosphatase is responsible for hydrolyzing orthophosphoric acid esters in an acid medium. The testicular acid phosphatase gene is up regulated by androgens and is down-regulated by estrogens (Yousef et al. 2001), CPF induced cell damage resulted in the release of acid phosphatase into the blood stream, hence reducing its level in the reproductive tissue. Previous studies reported a significant decrease in the acid phosphatase activity (Abraham and Wilfred, 2000; EL-Kashoury; 2009; EL-kashoury and Tag EL-Din, 2010; Dutta and Sahu; 2013). CYP evoked a significant elevation in serum level of acid phosphatase labialization of lysosomal system (Johal et al., 2003; Joshi et al., 2011).

CONCLUSION

An excessive exposure to CPF and CYP without restriction evoked deleterious changes in male reproductive system that may induce infertility. CPF and CYP impaired the reproductive functions through reduction of reproductive organs weight, in addition to alternative changes in the reproductive parameters such as sperm count, viability and morphology with deleterious effects on architecture of reproductive tissues. Alteration is more prominent in co-exposure to CPF and CYP so, the effect of both in a combination is more potent than using each as individual compound.

Acknowledgment

Sincere appreciation is expressed to **Dr. Mohammed Fawzy Hamid**, lecturer of

Pathology, Faculty of Veterinary Medicine Mansoura University for his faithful help to finish the histopathological findings in this study.

REFERENCES

- Abraham P. and Wilfred G. (2000):** Lysosomal enzymes in the pathogenesis of carbon tetrachloride induced injury to the kidney and testis in the rat. *Indian J. Pharmacol*, 32: 250–251.
- Ahmad L., Khan A., Khan M.Z., Hussain I., Mahmood F., Muhammad Kashif Sleemi M.K., a, Laeeq Akbar Lodhi L.A. and Imran Abdullah I. (2012):** Toxicopathological effects of cypermethrin upon male reproductive system in rabbits. *Pesticide Biochemistry and Physiology*, 103: 194–201.
- Alaa-Eldin E.A., El-Shafei D.A. and Abouhashem N.S. (2017):** Individual and combined effect of chlorpyrifos and cypermethrin on reproductive system of adult male albino rats. *Environ. Sci. Pollut. Res.*, 24: 1532–1543.
- Al-Hamdani N.M.H. and Yajurvedi H.N. (2010) :** Cypermethrin reversibly alters sperm count without altering fertility in mice. *Ecotoxicol Environ. Saf.*, 73: 1092–1097.
- Atessahin A., Yilmaz S., Karahan I., Pirincci I. and Tasdemir B. (2005):** The effects of vitamin E and selenium on cypermethrin-induced oxidative stress in rats. *Turk. J. Vet. Anim. Sci.*, 29: 385–91.

- Bearden H.J. and Fuquay J. W. (1980):** Applied Animal Reproduction Reston Publishing Co. Inc. Reston, Virginia, 157-165.
- Ben Abdallah F., Ben Slima A., Dammak I., Keskes-Ammar L. and Mallek Z. (2010):** Comparative effects of dimethoate and deltamethrin on reproductive system in male mice. *Andrologia*, 42: 182–186.
- Chen A., Bookstein, J.J. and Meldrum D.R. (1991):** Diagnosis of a testosterone-secreting adrenal adenoma by selective venous catheterization. *Fertil. Steril.*, 55: 1202-1203.
- Dutta A.L. and Sahu C.R. (2013):** Emblica officinalis Garden fruits extract ameliorates reproductive injury and oxidative testicular toxicity induced by chlorpyrifos in male rats. *Springer Plus.*, 2: 2-13.
- Ekaluo U.B., Ibiang Y.B., Ikpeme E.V., Ekanem B.E. and Erem F.A. (2013):** Effect of deltamethrin and ridomil on sperm parameters and reproductive hormones of male albino rats. *J. Toxicol Environ. Health Sci.*, 5(1): 9–14.
- Elbetieha A., Da'as S.I., Khamas W. and Darmani H. (2001):** Evaluation of the toxic potentials of cypermethrin pesticide on some reproductive and fertility parameters in the male rats. *Arch. Environ. Contam. Toxicol.*, 41(4): 522–528.
- Elelaimy I.A., Ibrahim H.M., Abdel Ghaffar F.R and Alawthan Y.S. (2012):** Evaluation of sub-chronic chlorpyrifos poisoning on immunological and biochemical changes in rats and protective effect of eugenol. *Journal of Applied Pharmaceutical Science*, 2(6): 51-61.
- EL-Kashoury A.A. (2009):** Influence of subchronic exposure of profenofos on biochemical markers and microelements in testicular tissue of rats. *Mars land Press J. Am*, 5(1): 19–28.
- El-Kashoury A.A. and Tag El-Din H.A. (2010):** Chlorpyrifos (From different sources) effect on testicular biochemistry of male albino rats. *Journal of American Science*, 6(7): 252–261.
- Ezeji E.U., Ogueri O.D., Udebuani A.Ch., Okereke J.N. and Obasi K.O. (2015):** Effect of dichlorovos on the fertility of adult male albino rats. *Nature and Science*, 13(12): 1-5.
- Fang L.Y., Chen P., Xia H.X., Jing L., and Chun X.L. (2013):** Effects of Cypermethrin on Male Reproductive System in Adult Rats. *Biomed. Environ. Sci.*, 26(3): 201-208.
- Fernandez-Botran R., Gorantla V., Sun X., Ren X., Perez-Abadia G., Crespo F.A. and Ray M. (2002):** Targeting of glycosaminoglycan-cytokine interactions as anovel therapeutic approach in allotransplantation1. *Transplantation*, 74(5): 623-629.
- Habing W., Pabst M. and Jakoby W.J. (1974):** A UV method for determination of Glutathione-S-Transeferase. *Biol. Chem.*, (249): 7130-7139.
- Heikal T.M., Mossa A.T., Ibrahim A.W. and Abdel-Hamid H.F. (2014):** Oxidative damage and reproductive toxicity associated with cyromazine and chlorpyrifos in male rats: the protective

- effects of green tea extract. *Res. J. Environ. Toxicol.*, 8: 53–67.
- Heikal T.M., Mossa A.T.H., Abdel Rasoul M.A. and Marei G.I.K. (2013):** The ameliorating effects of green tea extract against cyromazine and chlorpyrifos induced liver toxicity in male rats. *Asian G. Pharm. Clin. Res.*, 6: 48-55.
- Hummdi L.A., Abdelaziz E.H., Alalwani A.D. and Abualnasor E.A (2016):** Testicular toxicity of cypermethrin in adult and young male rats. *Indian Journal of applied research*, 6 (1): 293-300.
- Ikpeme E.V., Okonko L.E. and Udensi O.U. (2016):** Detrimental effects of chlorpyrifos and cypermethrin on reproductive physiology of male albino rat. *Research Journal of Environmental Toxicology*, 10(1): 68-74.
- Ikpeme E.V., Udensi O., Ekaluo U.B., Uyoh E.A., Asuquo B.O., Udoh F.V. and Udoh P.B. (2007):** Effect of crude extract of *Caricacapaja* seeds on the reproductive efficiency of male albino rats. *Global J Pure Applied. Sci.*, 13: 365–368.
- Johal, M.S., Sandhu G.S., and Kaur R. (2003):** Effects of furvelerate on acid and alkaline phosphatase activity in certain tissues on *Hetropneustes fossillis*. *Pollution Research*, 3: 309–13.
- Johnson M.R., Carter G., Grint C., et al (1983):** Relationship between ovarian steroids, gonadotropin and relaxin during the menstrual cycle. *Acta Endocrinol*, 129(2): 121-125.
- Joshi S.C., Bansal B. and Jasuja N.D. (2011):** Evaluation of reproductive and developmental toxicity of cypermethrin in male albino rats. *Toxicological & Environ Chemistry*, 93(3): 593–602.
- Joshi S.C., Mathur R. and Gulati N. (2007):** Testicular toxicity of chlorpyrifos (an organophosphate pesticide) in albino rat. *Toxicol Ind. Health*, 23(7): 439–444.
- Kalender Y., Kaya S. and Durak D. (2012):** Protective effects of catechin and quercetin on antioxidant status, lipid peroxidation and testishistoarchitecture induced by chlorpyrifos in male rats. *Environ. Toxicol. Pharmacol*, 33(2): 141–148.
- Kenfack A., NgoulaF., Dzeufiet P.D.W., Ngouateu O.B., MartineT.M.A, Chombong J.K., Zeukeng G.M.Z., Nyuysemo L.L., Guiekpe A.J.N., Nain T.P , Kamtchouing P., Tchoumboué J. and Vemo N.B. (2015):** Persistence of the reproductive toxicity of chlorpyrifos-ethyl in male Wistar rat, *Asian Pacific Journal of Reproduction*, 4(1): 37-40.
- Khan A., Hafiz H.A.M., Faridi, Ali A., Khan M.Z., Siddique M., Hussain I. and Ahmad M. (2009):** Effects of cypermethrin on some clinico-hematobiochemical and pathological parameters in male dwarf goats (*Capra hircus*). *Experimental and Toxicologic Pathology*, 61: 151–160.
- Khan S.M. and Kour G. (2007):** Subacute oral toxicity of chlorpyrifos and protective effect of green tea extract. *Pesticide and Biochemical Physiology*, 89: 118–123.
- Kind P. R. N. and King E. J. (1954):** *J. Clin. Path.*, 7: 322.
- Knobil E. (1980):** The neuroendocrine control of the menstrual cycle, *Rec. Prog. Horm. Res.*, 36: 52-88.
- Maharajan A., Narayanasamy Y., Ganapiriya V. and Shanmugavel K.**

- (2015): Histological alterations of a combination of Chlorpyrifos and Cypermethrin (Nurocombi) insecticide in the fresh water crab. *Paratelphusa jacquemontii* (Rathbun), *The Journal of Basic & Applied Zoology*, 72: 104–112.
- Mansour S.A. and Mossa H.A-T. (2010):** Oxidative damage, biochemical and histopathological alterations in rats exposed to chlorpyrifos and the antioxidant role of zinc, *Pest. Biochem. Physiol.*, 96 (1): 14–23.
- Montgomery, H. A. C and Dymock, J. F. (1961):** *Analyst*, 86, 414.
- Mosbah R., Yousef M.I., Maranghi F. and Mantovani A. (2014):** Protective role of *Nigella sativa* oil against reproductive toxicity, hormonal alterations, and oxidative damage induced by chlorpyrifos in male rats. *Toxicol Ind Health*.
- Nishikimi M., Roa N.A. and Yogik. (1972):** A colorimetric method for determination of serum Soperoxide dismutase. *Biochem. Bioph. Res Commun.*, 46: 849-854.
- Noaishi M.A., Allah A.A. and Afify M.M. (2012):** Oral and dermal exposure of chlorpyrifos and cypermethrin mixture induced cytogenetic, histopathological damage and oxidative stress in rats. *J. Am. Sci.* 9: 56–65.
- Ogutcu A., Suludere Z. and Kalender Y. (2008):** Dichlorvos-induced hepatotoxicity in rats and the protective effects of vitamins C and E. *Environmental Toxicology and Pharmacology*, 26(3): 355-361.
- Oyeyipo I.P, Raji Y. and Bolarinwa A.F. (2015):** Nitric oxide synthase inhibition ameliorates nicotine-induced sperm function decline in male rats. *Asian Pacific Journal of Reproduction*, 4(3): 212–216.
- Sai L., Li X., Liu Y., Guo Q., Xie L., Yu G., Bo C. and Zhang Z., Li L. (2014):** Effects of Chlorpyrifos on Reproductive Toxicology of Male Rats *Environmental Toxicology*, 29: 1083–1088.
- Satoh K. (1978):** Serum lipid peroxide in cerebrospinal disorder determined by a new colorimetric method. *Clinica. Chemical. Acta.*, 90: 37-43.
- Savithri Y., Sekhar P.R. and Reddy M.S. (2016):** Acute Toxicity of OP Pesticide Chlorpyrifos on Antioxidant Enzymes in Albino Rats, *Int. J. Pharm. Sci. Rev. Res.*, 37(1): 71-76.
- Sharma P. and Singh R. (2010):** Protective role of curcumin on lindane induced reproductive toxicity in male Wistar rats. *Bull. Environ. Contam. Toxicol.*, 84: 378–384.
- Sharma P., Huq A.U. and Singh R. (2014):** Cypermethrin-induced reproductive toxicity in the rat is prevented by resveratrol. *J. Hum. Reprod. Sci.*, 7(2): 99–106.
- Shittu M., Ambali S.F., Ayo J.O. et al (2012):** Evaluation of chronic chlorpyrifos-induced reproductive toxicity in male wistar rat: protective effects of vitamin C. *J. Exp. Integr. Med.*, 3(1): 23–30.
- Singh V. and Chaturvedi C.M. (2013):** Correlation of Nitric oxide and testicular activity in laboratory mouse, *Mus musculus*. *Int. J. Innov. Res. Sci, Eng. Techn.*, 2(3): 721-729.

- Soderlund D. M. (2012):** Molecular mechanisms of pyrethroid insecticide neurotoxicity: Recent advances. *Arch. Toxicol.*, 86: 165–181.
- Suvarna K.S., Layton C. and Bancroft J.D. (2012):** Bancroft's Theory and Practice of Histological Techniques E-Book. Elsevier Health Sciences.
- Umosen A.J., Ambali S.F., Ayo J.O., Mohammed B. and Uchendu C. (2012):** Alleviating effects of melatonin on oxidative changes in the testes and pituitary glands evoked by subacute chlorpyrifos administration in Wistar rats. *Asian Pacific Journal of Tropical Biomedicine*, 645-650.
- Uzun F.G., Kalender S., Durak D., Demir F. and Kalender Y. (2009):** Malathion induced testicular toxicity in male rats and the protective effect of vitamins C and E, *Food Chem. Toxicol.*, 47: 1903–1908.
- Wang X.Z., Liu S.S., Sun Y., Wu J.Y., Zhou Y.L. and Zhang J.H. (2009):** Betacypermethrin impairs reproductive function in male mice by inducing oxidative stress. *Theriogenology*, 72: 599–611.
- Wielgomas B., Krechniak J. (2007):** Toxicokinetic interactions of alphacypermethrin and chlorpyrifos in rats. *Pol. J. Environ. Stud.*, 16(2): 267.
- World Health Organization (2010):** The WHO Recommended Classification of Pesticides by Hazard and Guidelines to Classification 2009 (Report). World Health Organization. Retrieved 2014-07-09.
- Yao K.W. and Wang, J.D. (2008):** Progress in studies of the male reproductive toxicity of pyrethroid insecticides. *Zhonghua Nan Ke Xue.*, 14(3): 268-271.
- Yousef G.M., Diamandis M., Jung K. and Eleftherios P. (2001):** Molecular cloning of a novel human acid phosphatase gene that is highly expressed in the testes. *Genomics*, 74(3):385–395.
- Zhou S. P., Duan C. Q., Michelle W. H. G., Yang F. Z. and Wang X. H., (2011):** Individual and combined toxic effects of cypermethrin and chlorpyrifos on earthworm. *Journal of Environmental Sciences*, 23(4): 676–680.
- Zidan N.E.H.A. (2009):** Evaluation of the reproductive toxicity of chlorpyrifos methyl, diazinon and profenofos pesticides in male rats. *Int. J. Pharmacol.*, 5(1): 51–57.

الملخص العربي

التأثير السمي لتداخل الكلوربيريفوس والسيبرمثرين علي التكاثر في ذكور الفئران البيضاء

أسماء محمود النمكي، أمل عبد المنعم حلاوة، ممدوح محمد أبو المجد

قسم الطب الشرعي والسموم- كلية الطب البيطري- جامعة المنصورة- مصر

أجريت هذه التجربة لدراسة التأثير السمي لكل من مركبي الكلوربيريفوس و السايبرمثرين وكذلك الجمع بينهما علي الجهاز التناسلي في ذكور الفئران البالغة.

قسمت الفئران إلى أربعة مجموعات (عشرة فئران لكل مجموعة) عشوائيا. المجموعة الأولى ضابطة حيث تم تجريعها ٠,٥ مل من الماء المقطر، أعطيت المجموعة الثانية والثالثة والرابعة ١٠ ملجم / كجم من وزن الجسم كلوريدبيريفوس، ١٧,٢٢ ملجم / كجم من وزن الجسم من سيبرمثرين ، ٥ ملجم / كجم من وزن الجسم كلوربيريفوس + ٨,٦١ ملجم / كجم من وزن الجسم سيبرمثرين علي التوالي بواسطة انبوب الليي المعدي يوما بعد يوم لمدة ٢٦ يوما. في اليوم السادس والعشرين تم أخذ عينات الدم لفصل مصل الدم لقياس تركيز هرمونات الذكورة (التستوستيرون، هرمون تحفيز الجريبات و ليوتينيزنج هرمون) أيضا قياس تركيز إنزيم الأسيد فوسفاتيز. تم استخراج الجهاز التناسلي الذكري (الخصيتين، البربخ ، الحويصلة المنوية وغدة البروستاتا) وكذلك المخ والغدة النخامية لتحديد مدي تأثيرهم بهذه المبيدات. تم حفظ خصية من كل فأر في محلول الفوسفات المتعادل عند درجة حرارة ٢٠ درجة مئوية لمعاينة الإجهاد التأكسدي في النسيج المطحون. وقد استخدم ذيل البربخ للحصول علي الحيوانات المنوية لتقييم عددها ومدي حيويتها والتشوهات الحادثة. وقد استخدمت الخصية والبربخ الاخر لدراسة التغيرات الباثولوجية الحادثة.

وقد أظهرت النتائج أن التعرض لهذه المبيدات أدى إلي حدوث تغيرات شديدة خاصة في المجموعة التي تم تعرضها للمبيدين معا حيث وجد انخفاضا ملحوظا في وزن الأعضاء التناسلية، أيضا انخفاض ملحوظ في خصائص الحيوانات المنوية من حيث (عدد الحيوانات المنوية ومدي حيويتها) مع وجود نسبة عالية من التشوهات. أيضا وجود انخفاض معنوي في مستويات المصل من الهرمونات التناسلية (التستوستيرون، هرمون تحفيز الجريبات الهرمون الملوتن). علاوة على ذلك، فإن كلا من الكلوربيريفوس و السايبرمثرين يسببا إجهاد تأكسدي شديد حيث لوحظ زيادة معنوية في تركيز اللييد بيروكسيد والمعبر عنه إنتاج زيادة تركيز المالون داي ألدهيد ، وانخفاض ملحوظ في نشاط الانزيمات المضادة للأكسدة (سوبراكسيد ديسميوتيز و الجلوتاثيون-اس- ترانسفيراز) مع زيادة ملحوظة في مستوى النيتريك أكسيد وزيادة في نشاط حمض الفوسفاتيز الكلي في الدم مع انخفاض نشاط حمض الفوسفاتيز بالبروستاتا

التي تؤكد إصابة الخصية نتيجة استخدام كلا المركبين. وتشير الصفة التشريحية إلى حدوث تغيرات باثولوجية في أنسجة الجهاز التناسلي وخلايا المخ والغدة النخامية.

الخلاصة:

استخدام كلا من الكلوربيريفوس و السبيرمثرين له تأثير ضار علي الجهاز التناسلي للذكور مما أدى إلى انخفاض ملحوظ في وزن الأعضاء التناسلية، عدد الحيوانات المنوية ومدى حيويتها والتشوهات الحادثة فيها. وعلاوة على ذلك، حدوث تغيرات مرضية في أنسجة الجهاز التناسلي والأنسجة العصبية (المخ والغدة النخامية). فقد لوحظ أن التغيرات الناتجة عن مجموعة الخليط أكثر وضوحا مقارنة بالتغيرات الناتجة عن استخدام كل مركب علي حدة . من ذلك نستنتج أن تأثير كلا المركبين في صورة خليط نتيجة التأثير التآزري هو أكثر ضررا .