

## **ROLE OF FERMENTED MILK IN TREATING THE HISTOPATHOLOGICAL AND THE HISTOCHEMICAL CHANGES INDUCED IN LIVER OF MICE BY A TOXIC MUTAGEN**

**AMNAH A. H. RAYES \* AND NAYRA SH. MEHANNA\*\***

\*Biology Department - Faculty of Applied Sciences, Umm Al-Qura University - Kingdom of Saudi Arabia -

\*\*Dairy department, National Research Center – Egypt.

### **ABSTRACT**

The present study was performed to study the potential effects of the intake of fermented milk containing the probiotic bacteria: *Lactobacillus spp* and *Bifidobacterium spp* as a supplementation for daily food. The study also emphasizes on possibility to cease the hepatic lesions induced by the oral administration of a carcinogenic mutagen 3 amino-I methyl -5H-pyrido (4, 3-b) indole. Twenty male mature albino mice 8-10 weeks old weighing  $20 \pm 3$  grams were divided into four groups each consisted of 5 mice. A normal control group was fed the rodent pellet for 30 days .Other 3groups (A), (B) &(C) were given orally one dose of the toxic mutagen (0.25mg for each mouse) at the beginning of the experimental period and fed the normal diets. At the 15<sup>th</sup> day, mice of group (A) were dissected while the mice of group (B) were given a second dose of the toxic mutagen then continued feeding normal diets further two weeks. Animals of group (C) were given the second dose of the toxic mutagen at the 15<sup>th</sup> day and started feeding fermented milk (30 gm / mouse daily) further 15 days. The quality of life was measured by specific strain count in stole, and investigating the Histopathological and histochemical alterations in liver structure.

The variable count of *Lac.sp* and *Bif.sp* in stole of mice indicate that the potentiating effect of the ingestion of fermented milk by treated mice. There was also amelioration in hepatic architecture with less histopathological alternations after feeding the fermented milk. Moreover, the presented histochemical study recorded slight depletion in the total carbohydrate and total protein contents only in group C in comparison with controls.

**Key words:** Fermented milk - liver - probiotic – Histology

## INTRODUCTION

Fermented milk contains lactobacilli and bifidobacteria and other microorganisms which have complex nutritional requirements such as carbohydrates, amino acids, peptides, fatty esters salts, nucleic acid derivatives, and vitamin which vary markedly from species to species.

Many beneficial effects of fermented milk were observed in many studies such as prevention of pathogen colonization (Sandine 1979), lowering serum cholesterol (Zommara *et al.*, 1996), reduction of inflammatory reactions (Perdigon *et al.* (1991), prevention of cancer (McIntosh *et al.*, 1999 and Perdigon, *et al.*, 2001), and stimulation of immunomodulatory cells (Rolfe, 2000 and Perdigon, 2005).

The diet contains various mutagens and carcinogens that can be classified into three groups: naturally occurring chemicals, synthetic compounds and compounds produced by cooking includes polycyclic aromatic hydrocarbons and heterocyclic amines (HCAs). HCAs are mutagenic and have a multiplicative interactive interaction for carcinogenicity because they can change DNA directly and cause cell division at high doses (Gold *et al.*, 1993, Nagao and Sugimura, 1993; Aji *et al.*, 1994 & Synderwine *et al.*, 1998). Tavan *et al.*, (2002) reported that fermented milk containing either *Streptococcus thermophilus* or *Bifidobacterium animalis* inhibited the induction of preneoplastic lesions (aberrant crypt foci (ACF) in the colon ) and DNA migration caused by a HCA mixture containing (2-amino-3-methyl-3H-imidazo (4,5 - f) quinoline (I Q), 2-amino-3,4-dimethyl- 3H- imidazo (4,5-f) quinoline (Mel Q ) and 2-amino-1methyl-6-phenylimidazo (4,5-b) pyridine (PhIP) (ratio 1:1:1). Huang *et al.*, (2003) used 2 amino-3,4 dimethylimidazo (4,5-f ) quinolin for induction of liver tumors in mice.

The present study was performed on male mature albino mice to investigate the protective effect of ingesting fermented milk of cows that is containing probiotic bacteria against carcinogenicity of liver induced by the toxic mutagen 3 amino-1 methyl -5H-pyrido (4, 3-b) indole.

## MATERIAL AND METHODS

### I. Animals:

Twenty male albino mice (8-10 wk old) with an average initial body weight of  $21 \pm 3$ g were used in the present work. Animals were placed in individual metabolic cages and were housed in a room that was maintained at a constant

## ROLE OF FERMENTED MILK IN TREATING THE HISTOPATHOLOGICAL

temperature of  $22^{\circ} \pm 2^{\circ}\text{C}$ , and a relative humidity of  $60 \pm 5\%$ . Mice were housed on a 12-h light: dark schedule, with free access to water and standard diet containing (g/100 g): 64 starch, 23 protein, 3.5 fat, 5 fiber, 1 vitamin mixture and 3 salt mixtures.

Animals were divided into four groups of five mice each. The first group (control) received basal diets only for 4 weeks. The other three groups were treated orally with two doses of the toxic mutagen (was kindly provided from king Abd El-Aziz University), the first was administered at the beginning of the experiment and the second after two weeks. Groups A & B were fed by basal diets. At the 15<sup>th</sup> day animals of group (A) were dissected while the mice of group (B) were given a second dose of the toxic mutagen then continued feeding normal diets) further 15 days. Animals of group (C) were given the second dose of the toxic mutagen at the 15<sup>th</sup> day and started feeding fermented milk. (30 gm / mouse daily) which contain *Lac.sp.* and *Bif.sp.* (the count was more than  $10^8$ ) further 15 days. The fecal samples were collected at the beginning of the experimental period and after one day, 7, 14, 15 and 28 days. On the last day of the experimental period the mice were killed by carbon dioxide then dissected to process their liver for light microscopy.

### II. a. Natural fermented milk (NFM):

The natural fermented milk of cows was collected from areas around Makka (five different sources). The (NFM) which contain *Lac.sp.* and *Bif.sp.* (Rayaes et al.,2006 ) was used as mother culture to make daily fermented milk diets to feed the mice.

### b. Preparation of fermented milk:

Fresh cow milk (8.6% solid not fat, 3.3% fat) was heated to  $90^{\circ}\text{C}$  for 10 minutes, and then cooled to  $40^{\circ}\text{C}$ . NFM was inoculated at 2% level (volume/volume), then incubated at  $37^{\circ}\text{C}$ .

## III Analysis:

**1.Fermented milk:** *Lactobacillus spp.* was counted on (Oxoid) (*De Man et al., 1960*) while *Bifidobacterium spp.* enumerated (Sigma Chemical Co., St. Louis, Mo) according to Blanchette *et al.* (1996) using modified MRS agar with 0.05 L-cysteine HCl and incubated anaerobically using Gen Kits in Oxoid jar for 48 h at  $37^{\circ}\text{C}$ .

### 2. Fecal Microbial Analysis

All fecal samples were collected fresh by squeezing gently the rectal area of the mice. The fecal pellets were immediately placed in tubes kept in anaerobic jars

and the analysis was carried out within 30 to 60 min of collection. Anaerobic conditions were maintained as far as possible during the analysis. Following homogenization, series of 10-fold dilutions of the specimens was made in sterile phosphate buffer.

Triplicate plates were made of each sample. Strains of *E. coli* were counted on Brilliant green agar (Oxoid) supplemented with 0.5% glucose (FAO, Reported, 1979) and MRS agar or MRS with 0.05 L-cysteine HCl agar for *Lactobacillus* and *Bifidobacterium* respectively. Plates were incubated anaerobically in an anaerobic chamber (Gen Kits in Oxoid jar) for 3 d at 37° C. Plates were incubated at 37° C for 2 d. for the enumeration of aerobic organisms (*E. coli*).

## HISTOPATHOLOGICAL STUDY

Liver of animals of all groups were processed for histological and histochemical studies. Paraffin sections of 7µm thickness of liver were stained by haematoxylin and eosin method for the histological studies. For the histochemical examination, sections were stained by:

1-The periodic acid-Schiff (PAS) (Drury and Wallington, 1980).

2-Mercuric bromophenol blue procedure for general proteins (Mazia et al., 1953)

## STATISTICAL ANALYSIS

Results obtained were subjected to Student's t-test using SPSS (1993) version 6.0. Standard error and level of significance were calculated and compared to control animals or with the values of before administration (0 d) of the respective group.

## RESULTS

### MICROBIAL ANALYSIS:

#### a- *Bifidobacterium* count:

We noticed that the count slightly increased in control group stool which fed on basal meal without any treatment, while in other groups (A&B&C) in the first day the stool showed a normal count but in the second day after treatment by the mutagenic substance the count dramatically decreased and in the same Petri dishes phage plaques were observed. The same fig showed that after 7 days the normal flora grew again but with very low count. Animals of group (A) were killed after two weeks to examine the liver tissue, group (B&C) were treated on the day 15 with a second dose of the toxic mutagenic substance, natural flora of

## ROLE OF FERMENTED MILK IN TREATING THE HISTOPATHOLOGICAL

*B.spp* didn't grow again in group (B). ,but contrarily, when mice of group (C) fed on natural fermented milk containing *B.spp* for 2 weeks ,the count of it increased to be nearly equal to the normal count .

### b- Lactobacillus count:

The same observation was present in the case of *L. sp* count (fig2), but the Lactobacillus strain didn't grow absolutely after the first treatment in all groups. When mice fed by the natural fermented milk containing lactobacillus strain after the second treatment the count increased again.

### c- E. coli count:

Fig (3) showed the log count of *E. coli* in mice stole. The normal flora increased during four weeks in control group, while in other groups which were treated by the mutagenic substance the flora disappeared, with present phage plaques, but it increased again to two weeks and repeated the same behaviour in group B&C after the second treatment. In group C the increase of *E .coli* count was significantly lesser than the increasein group B.

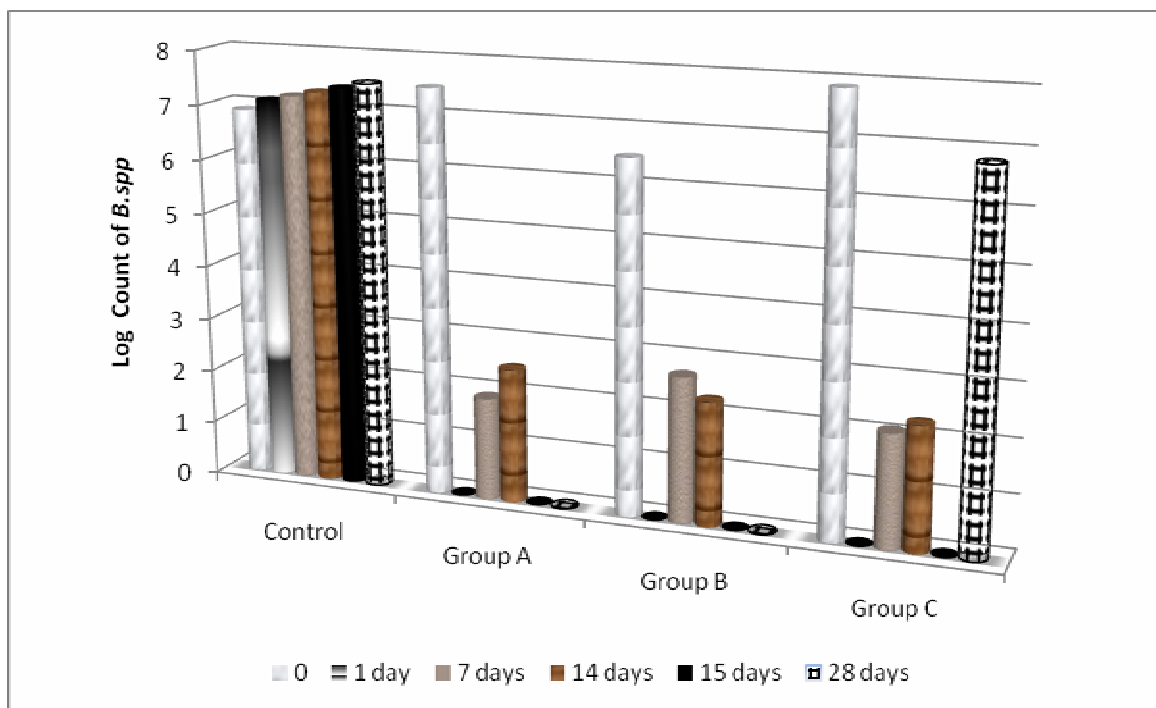


Fig (1) illustrated the log count of *B.spp* in stole of mice during four weeks.

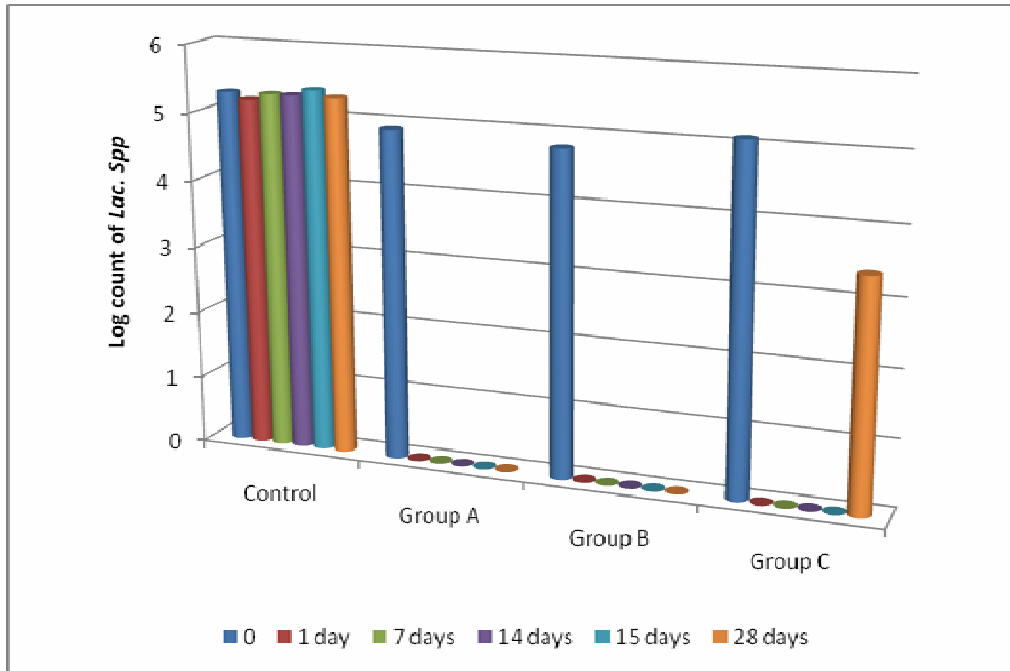


Fig (2): Lactobacillus count in stole of treated mice during fourweeks:

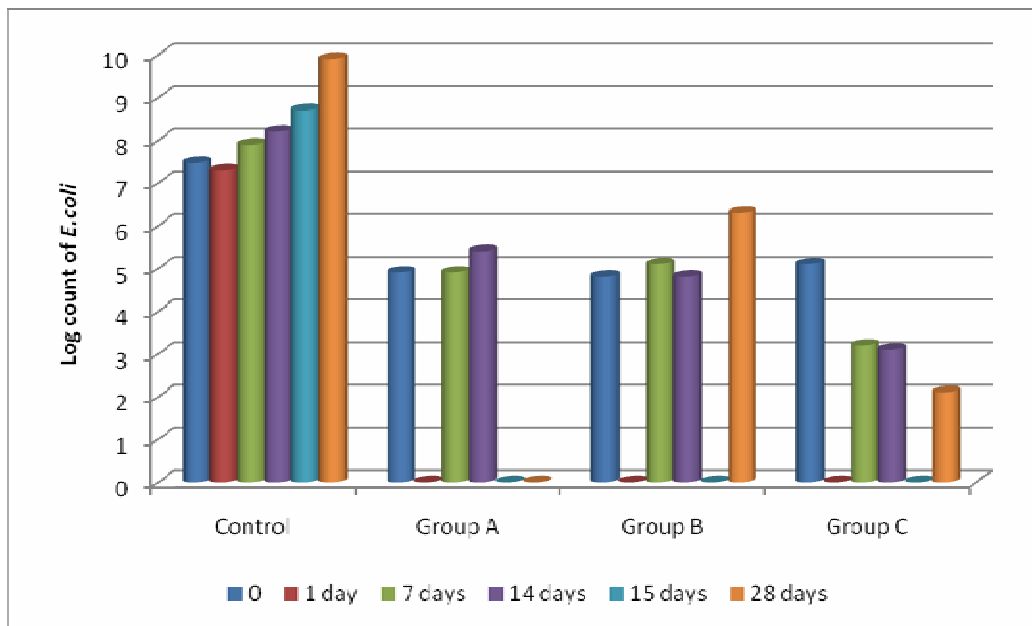


Fig (3): E.coli count in stole of treated mice during four weeks

## **ROLE OF FERMENTED MILK IN TREATING THE HISTOPATHOLOGICAL**

### **HISTOPATHOLOGICAL AND HISTOCHEMICAL INVESTIGATIONS:**

Gross pathological changes revealed primary lesions only in liver of mutagen treated animals .They showed yellowish red areas in their surface. Also masses of fats were observed in the visceral cavity in all groups but increased in mutagen treated mice. No macroscopical changes in any of the other organs were observed.

#### **Plate I,**

Fig (1 – A) showed histological structure of control liver:

Liver sections of these animals treated with one dose of the mutagen for 2 weeks showed some alterations, congestion and dilations in the central blood vessels (1 – B). Many patches of hepatocytes showed inflammatory appearance, vacuolations in cytoplasm, megalocytosis as well as binucleated cells and pyknotic nuclei( Fig1-C).Also, features of hepatic necrosis appeared in some areas of the liver tissue ( 1 – D ).

Animals given 2 doses of toxic mutagen at the day 15 of the experiment showed more severe effects were observed in vessels and sinusoids, congestion and strange dilations in blood vessels, atresia in hepatocytes (Fig 1-E.). Furthermore, tumors and focal areas of hepatic necrosis with pyknotic nuclei and hemorrhagies also were spotted in these sections (figs 1 – F & G).

Histopathological investigation of liver of treated mice received two doses of toxic mutagen at the days 0 & 15 of the experimental period then fed fermented milk 2weeks (gp C) showed many alterations which indicated liver damage and hepatotoxicity, yet, in addition to these alterations many regions along the hepatic tissue appeared healthy and showed criteria of improvement ( Fig 1 – J).

### **HISTOCHEMICAL INVESTIGATIONS:**

#### **Plates II & III**

The histochemical staining of sections with PAS reaction for total polysaccharides and bromophenol blue for general total proteins manifested normal pattern in liver sections from control mice (Figs 2-A & 3-A).

In sections of mice from group A, the glycogen and general total protein contents showed stainability nearly equal to that of controls (Figs.2 – B & 3 – B). Animals of group B showed a slight increase in polysaccharides and total protein contents more than controls (Figs 2 – C & 3 – C). On the other hand, sections of livers of animals from group C showed an obvious decrease in amount of

polysaccharides (Fig.2 – D) and the amount of the general total proteins (Figs 3 – D & 3 – E).

## DISCUSSION

In our previous study (Rayes *et al.*, 2006), the results indicated that fermented cow milk which contains *Lac. sp* and *Bif. sp*. has protective effects dependant on its anti-microbial properties. Also it enhances the endogenous intestinal probiotic bacteria that have several beneficial effects (i.e. detoxification and antigen toxicity) and stimulation of immune modulator cells. In this paper the aim of the study is to know if the fermented milk has ability to repair the tissue to their normal case. Presence of bifidobacteria and lactobacillus in stool at the beginning of the experiment indicated that this kind is naturally present in digestive system of mice induce the disappearance of bacterial strains after treatment with the mutagenic substance may be due to the toxic effect of this substance as some other chemical materials which induce the bacteriophage (Patrick and Matthew, 2002 and Christiane *et al.*, 2006). Induction of bacteriophage refers to lysis of bacteria. After the second treatment by carcinogenic substance the natural flora (*Bifidobacteria and lactobacillus*) disappear completely but contrarily, when mice of group (C) fed on natural fermented milk containing *B.spp* for 2 weeks, the count of it increased to be nearly equal to the normal count. These results indicate that feeding the mice on fermented milk keeps the healthy flora in the gastro intestinal duct. Also, in group C the increase of *E.coli* count was significantly lower than the increase in group (B), these results may be due to the inhibitor effect of *Bif. spp* and *Lac.spp* on it (Liévin *et al.*, 2000)

Histological investigations of the liver sections of treated mice from all groups revealed many alternative changes post administration of the toxic mutagen. Some histological toxic effects in the liver glands were observed such as congestion and dilations in the blood vessels and blood sinusoids. Blood infiltration by chronic inflammatory cells, necrotic areas and hemorrhagic spots in the sections from group (A) which received one dose of the toxic mutagen and showed progressive incidence in livers of group (B) which received two doses of the toxic mutagen.

This is supported by the work of Walter and Israel (1974) who illustrated that necrotic cells act as irritant substance attracting inflammatory cells. El-Banhawy *et al.*, (1974) described the vacuolation of hepatocytes as ballooning degeneration and interpreted it as a kind of cellular defensive mechanism against injurious substances. They pointed that the cellular degeneration might be



## ROLE OF FERMENTED MILK IN TREATING THE HISTOPATHOLOGICAL

attributed to liberation of acid hydrolases released from the destructive lysosome to facilitate the process of autolysis. Robbins *et al* (1984) reported that hepatic failure might be a consequence of toxic damage by drugs or any toxic substance. Furthermore, Fawcett(1986) reported that the changes leading to active hepatitis might be attributed to the fact that hepatocytes play a key role in body metabolism and they are greatly affected by the local concentration of any toxic substances. Fermented milk containing either *Streptococcus thermophilus* or *Bifidobacterium animalis* inhibited the induction of preneoplastic lesions (aberrant crypt foci (ACF) in the colon ) and DNA migration caused by a HCA mixture containing ( 2-amino-3-methyl-3H-imidazo ( 4,5 – f ) quinoline ( I Q ),2-amino-3,4-dimethyl-3H- imidazo (4,5-f) quinoline (Mel Q ) and 2-amino-1methyl-6-phenylimidazo (4,5-b) pyridine (PhIP) (ratio 1:1:1) (Tavan *et al.*,(2002). Huang *et al.*, ( 2003) used 2 amino-3,4 dimethylimidazo (4,5-f ) quinolin for induction of liver tumors in mice. Similar results were designated by many authors were attributed to toxic damage by drugs or any toxic substance (El-Mofty and Sakr 1988, El-Mofty *et al.*, 1989, El-Banhawy 1993, Mohammed and El-Naggar 1995, Abdel Mageid *et al.*, 1997, Abdel Mageid and Heibashy 2000, Abdel Mageid 2001, Abdel Hameed 2004, Abdel Maguid *et al.*, 2004 and Yousif (2005)

The histological examination of liver sections from group(C )revealed some alterations less than that noticed in groups A and B such as dilations and congestion of blood vessels lead to bleeding in some areas adjacent to these vessels, reduction in vacuolations of the cytoplasm and nuclei and less degenerative changes These results indicated that fermented milk stimulated the immunomodulatory system and the blood circulation, consequently, a large quantity of blood was drained to the liver lead to enlargement in the diameter of the blood vessels and dilations in the blood sinusoids .The incidence of chronic inflammatory cells, necrotic areas and the death of some hepatocytes surrounding the blood vessels is attributable to the effect of the 2doses of the toxic substance. At the same time, an obvious tissue improvement and more healthy hepatic lobules were noticed in the sections. These results indicated that feeding these mice on the fermented milk repaired the slightly damaged areas and prevented the progressive damage effects of the toxic mutagen in these areas while those which were severely damaged remained.

Renner and Munzner (1991) examined the possible actions of probiotics mainly lactic acid bacteria using in vitro and in vivo test systems. Their studies revealed that *L. casei* showed high antimutagenic activity on mutagenicity induced by nitrosated beef extract only without 59 mix, whereas Omniflora (a lyophilized preparation) of lactobacilli and *E. coli* and its cellfree culture broth exhibited antimutagenic action only on beef extract. The authors proved that the

induced chromosome aberrations and the micronuclei were reduced by up to 0% by the lactobacilli. Also Oytayo *et al* (2003) made a study confirmed the protective effects of *Lactobacillus acidophilus* and *Lactobacillus* isolated from fresh cow milk against the pathogenic effects in vivo. Also, many authors as well, made studies confirmed that fermented milk is a probiotic containing microorganisms having a complex nutritional requirements. Their studies investigated many beneficial effects for the fermented milk and confirmed its role in prevention of pathogenic colonization, reduction of inflammatory reactions (Perdigon *et al.*, 1991&2002 lowering the serum cholesterol (Zommara *et al.*, 1996). prevention of cancers, (Takagi *et al.*, 1999), and stimulation of immunomodulatory system, Rolfe 2000, Perdigon *et al.*, 2001&2005 )The present study proved that the observed changes which are due to the direct effect of the toxicity by the mutagen were to some extent reduced by fermented milk ingestion as indicated by maintaining many healthy parts in the liver and keeping the animals survival.

The histochemical results showed that the total carbohydrate and protein contents in groups A & B were nearly similar to those in controls. A deeply positive reaction in PAS preparations was observed in the outer peripheral hepatocytes, walls of the central veins and the hepatocytes surrounding it and the reddish stained particles of glycogen appeared occasionally at one pole of the hepatic cell. These observations are in agreement with those represented by Ahlersova *et al.*, (1981); El-Gharib *et al.*, (1999) and Mohammed and El-Naggar (1995). The slight depletion of PAS positive material in the sections of the liver tissue from group (C) was most probably consequent to the degenerative changes manifested to this study. The same results were confirmed by Mohammed and El-Naggar (1995) and Abd El Maguid *et al.*, (2004).

In bromophenol blue preparations, total proteins in sections from all groups were deeply stained in the surface peripheral layer, walls lining the central veins and hepatocytes surrounding the central veins. In some lobules, some areas appeared scattered in the liver sections from which received the toxic substance and were more intensely stained than the surrounding hepatocytes. The slight depletion in general total protein contents in hepatocytes in group (C) was confirmed by Mohammed and El-Naggar (1995) and Abd El Maguid *et al.*, (2004).

The variable count of *Lac.sp* and *Bif.sp* in stool of mice indicated that the potentiation of the ingestion of fermented milk to treated mice managed to present ameliorated hepatic architecture with less histopathological alternations after feeding the fermented milk. Moreover, the present histochemical results recorded

## ROLE OF FERMENTED MILK IN TREATING THE HISTOPATHOLOGICAL

slight depletion in the total carbohydrate and total protein contents only in group C in comparison with controls.

Similarly, FM supplementation to mutagen treated animals revealed marked amendment of histochemical parameters. Hereby the potential effect of FM ingestion was capable of endorsing protective measures to hepatic tissue architecture and decreasing the toxic effect induced by mutagen administration.

### REFERENCES

1. Abdel Hameed, T. F. (2004) :Light and electron microscopic studies on the effect of orally administrated formalin on liver and kidney of Guinea pig . *J. Egypt Ger. Soc. Zool. (36) C Histology and Histochemistry. 45 (C) : 203-224.*
2. Abdel-Mageid, S.(2001): Evaluation of the protective role of vitamin E. (against rat renal toxicity by gluten derived peptides from wheat .*J. Egypt Ger. Soc. Zool Histology and Histochemistry. 36 (C): p 33-59.*
3. Abdel Mageid S. A. and Heibashy, M. I. A. (2000): Therapeutic and prophylactic intake of allopurinol and garlic oil in renal failure rats induced by gentamicin experimental studies on the liver. *Union Arab boil., Cairo 13(A): Zoology 505-530.*
4. Abdel Mageid S. Wahba S. M. R. and Fouad M. A. (1997): Role of temzapam and or nicotine administration and histochemical study. *Egypt. J. Histol, 20(2) : 453-470.*
5. Abdel Maguid,A.; Gharib,R. and Ahmed K. A. (2004): possible protective role of Melatonin Against Radiation induced Histopathological and Histochemical Changes in liver of male albino rats. *J Egypt. Ger. Soc. Zool. (45c) Histology & Histochemistry.1-13.*
6. Ahlersova, E. ; Ahlers, I. ; and Slavkovska, M. (1981): Metabolic changes after non lethal X irradiation of rats *Folia Biol.; 27 : 404.*
7. Aji, T.; Matsuoka, H. ; Ishii, A. ; Arimoto, S. ; and Hayatsu, H. (1994): Retention of a mutagen 3-amino-1-methyl-5H-pyrido (4,3 b) indole ( trp 2-2) in the liver of mice infected with *Schistosoma japonicum* . *Mutation Research Fundamental and Molecular Mechanisms of Mutagenesis. 305 (2):265-272.*
8. Blanchette L. ; Roy D; Belanger G and Guathier S. F. (1996). Production of cottage cheese using dressing fermented by Bifidobacteria. *J Dairy Sci.; 79:8- 15.*

9. Christiane G., Johanna K., and Christiane W.(2006) Ciprofloxacin and Trimethoprim Cause Phage Induction and Virulence Modulation in *Staphylococcus aureus*. *Antimicrobial agents and chemotherapy*, 50, (1): 171–177.
10. De Man, J.C.; Rogosa, M; and Sharpe, M. E. (1960): A medium for the cultivation of lactobacilli, *Int. J. Appl. Bacteriol.* 23: 130-135.
11. Drury, R.A. and Wallington, E.A. (1980): Carleton's Histological technique" 5th Edition published by *Oxford University press*. London, New York, Toronto 240-234.
12. El-Banhawy, M. A.; Al-Zahaby, S. A.; Sanad. S. M. and Hashem A. M. (1993): Histopathological studies on the effect of the anticoagulant Rodenticide brodifacoum on the rat. *J. Egypt. Ger. Soc. Zool.*, 12 (C) : 185-227.
13. EL-Banhawy, M. A. (1974): Histological, cytological and histochemical effects of insecticides on insect and mammalian tissues. Symp. on the use of isotopes in pesticides and pest control. *Beirut, Lebanon.*, pp. 113-123.
14. El-Gharib, R.F. ; Fahmy, N. ; Abd El-Maguid, A. ; and Saber, F. H. (1999): Studies on radiation injury and recovery on liver using silymarin. *Egypt J. Histol*, 22 (122): 111-124.
15. El-Mofty M. M. and Sakr S. A. (1988). The induction of Neoplastic Lesions by Aflatoxin-B1 in the Egyptian Toad. (*Bufo regularis*) *Nutr Cancer* 11: 55-59.
16. El Mofty M. M.; Sakr S. A.; Osman B. A. and Toulan B. A. (1989): Carcinogenic effect of biscuits made of flour infested with *Tribolium castaneum* in *Bufo regularis*. *Oncology* 46: 63-65.
17. FAO/WHO, (1979):“Health and nutritional properties of probiotics in food including powder milk with live lactic acid bacteria”, Cordoba, *Argentina*, 30 [suppl 2]: S23-S33.
18. Fawcett , D. W. (1986): A textbook of Histology. 11th ed. W. B., Saunders Company, *Igakushoin, Philadelphia*.
19. Gold L. S. ; Slone, T. H. ; Stem B. R. and Bernstein, L. (1993): Comparison of Target organs of carcinogenicity for mutagenic and non-mutagenic chemicals. *Mutation Research Fundamental and Molecular Mechanisms of Mutagenesis* 286 (1): 75 – 100.
20. Huang, H. ; Ushijima, T. ; Nagao, M. ; Sugimura T. ; and Ohgaki, H. (2003): B-cateninb mutations in liver tumors induced by 2-amino-

## ROLE OF FERMENTED MILK IN TREATING THE HISTOPATHOLOGICAL

- 3, 4 dimethylimidazo (4, 5, F) quinolin in CDF mice. Short Communication *Cancer Letters* 198 (1): 29-35.
21. Mazai, d. ; Brewe, P.A. and Affert, M. (1953): The cytochemical staining and measurement of protein with mercuric bromophenol blue. *J. Biol. Bull.* 104: 57-64.
22. McIntosh, G. H. ; Toyle, P.J. ; and Playne, M.J. (1999): A probiotic strain of *L. acidophilus* reduces DMH induced large intestinal tumors in male Sprague-dawley rats. *Nutr cancer* 35: 153-159.
23. Mohammed, A. A. and El-Naggar, M. S. (1995): Histological and Histochemical study on the effect of monosodium glutamate on the albino rat's kidney. *The new Egypt. J. of MED.*, 12 (2): 182-189..
24. Nagao, M. and Sugimura, T. (1993) : (eds), Food Borne Carcinogenesis: Heterocyclic Amines. Wiley, New York, NY, pp. 5-29.
25. Oyetayo, V.O. ; Adetuyi, F.C. and Akinyosoye, F.A. (2003): Safety and protective effect of *Lactobacillus acidophilus* and *Lactobacillus casei* used as probiotic agent in vivo. *Afr. J. Biotechnol. Vol. 2 (11): pp. 448-452.*
26. Patrick L. W. and Matthew K. W. (2002) infection and immunity. *Bacteriophage Control of Bacterial Virulence* 70(8): 3985-3993.
27. Perdigon, G. ; Alvarez, S. and Pesce-de Ruiz Hdgado, A. (1991): Immuno-adjuvant activity of oral *Lactobacillus casei* influence of does on the secretary immune response and protective capacity in intestinal infections, *J. Dairy Res.* 58: 485-496.
28. Perdigón, G. ; Fuller, R. ; and Raya, R. (2005): Lactic acid bacteria and their effect on the immune system. *Curr Issues Intest Microbiol.*;2:27-42.
29. Perdigón, G. ; de Moreno ,de L. A. ; Valdez, J. and Rachid, M. (2002): Role of yoghurt in the prevention of colon cancer. *Eur J Clin Nutr.*;56(Suppl 3):S65-S68. .
30. Perdigón, G. ; Vintini, E. ; Alvarez, S. ; Medina, M. and Medici, M. (2001): Study of the possible mechanisms involved in the mucosal immune system activation by lactic acid bacteria. *J. Dairy Sci.*;82:1108-1114.
31. Rayes, A. A. H.; El-Naggar, M .M .S. and Mehanna, Sh. M. (2006): The effect of natural fermented milk in the protection of liver from cancer *Sc. J. Az. Med. Fac. (Girls).* 27 92):2027-2046.

32. Renner, H. W. and Minzner ,R.(1991):The possible role of probiotics as dietary antimutagens *Mutation Research Letters*, 262 (4) p239-245 .
33. Robbins, S. L.; Carton, . S. and Kumar ,V.(1984): Pathologic basis of disease 3rd ed. W. B. Saunders Company, *Igoka, Shoin Philadelphia*.
34. Rolfe, R. D. (2000): The role of Probiotics cultures in the control of: gastroin health *J. Nutr.* 130 (25): 396S – 402 S.
35. Sandine, W.E. (1979): Role of lactobacillus in the intestinal tract *Food I* 42: 259-262.
36. Synderwine, E. G.; Sadrieh, N.; King, R. S. and Schut, H. A. J.(1998): Formation of DNA adducts of the food-derived 2-amino-9H-pyrido-[2,3-b] indole (A(a)C) and bioassay of mammary gland carcinogenicity in Sprague-Dawley rats. *Food and Chemical Toxicology*, 36 (12): 1033-1041.
37. SPSS for Windows, User's Guide: Basic System, release 6.0. 1993. SPSS Inc., *Chicago, IL*.
38. Takagi, A.; Matsuzaki, T. Sato; M. Norotomi, M., and Yokokura, T. (1999): Inhibitory effect of oral administration of Lactobacillus casei on 3-methyleholanthrene-induced carcinogenesis in mice *.Med. Microbial Immunol*, 188: 111-116.
39. Tavan,E. ;Cayuela, C.; Antoine, J. M.; Tragnan, G.;Chaugier,C. and Cassand ,P. (2002): Effects of dairy products on heterocyclic aromatic –induced rat colon carcinogenesis. *carcinogenesis.*, 23 ; 577-483.
40. Liévina V.; Peiffera I.; Hudaulta S.; Rochatb F.; Brassartb D.; Neeserb J. R. and Servina A. L. (2000): *B.* strains from resident infant human gastrointestinal microflora exert antimicrobial activity. *Gut*; 47:646-652.
41. Walter , J. and Israeal, M.(1974): General pathology. 4th edn., *Churchill Livingstone, Edinburgh. London, NewYork*.
42. Yousif, J. M. A. (2005): Study on the biochemical therapeutic effects of some common plants on liver cancer. A thesis of (Ph.D) in *Science Girl's collage of Education, Jeddah-K. S.A*.
43. Zommara, M. ; Tachibana, N. ; Sakono, M. ; Suzuki, Y., Oda, T. ; Hashiba, H.; and Imaizumi, K. (1996): Whey from cultured skim milk decreases. serum cholesterol and increases antioxidant enzymes in liver and red blood cells in *rats Nutrition research*, 16(2) : 293-302.

**LEGENDED OF PLATES**

**Histological results:**

**Plate I.**

**Fig (1 – A)**

Liver section of a control mouse showing the normal structure of the liver of mammals. (HX – E, X400).

**Fig (1 – B)**

Liver section of a mature mouse after 2 weeks post administration of toxic mutagen (group A) showing dissociation of the endothelium lining the blood vessel which appeared congested and dilated, infiltration by chronic inflammatory cells and rupture in the vascular wall, vacuolations of cytoplasm. Megalocytosis as well as binucleated cells and pyknotic nuclei.  
(Hx – E, x 400).

**Fig (1 – C)**

Liver section of a treated mouse (group A) two weeks post administration of the mutagenic substance showing a focal hemorrhagic area, Megalocytosis, binucleated cells, infiltration by chronic inflammatory cells, pyknotic nuclei and vacuolation of cytoplasm.

**Fig (1 – D)**

Liver section of a treated mouse (group A) demonstrating a severe damage, focal area of hepatic necrosis with pyknotic nuclei, Megalocytosis, binucleated cells.  
( HX – E, X 400 ).

**Fig (1 – E)**

liver section of a mature mouse ( group B ) one month after treatment by toxic mutagen showing dissociation in endothelium of blood vessel, congestion and strange dilations in the blood vessel and sinusoids, atresia in hepatocytes and pyknotic nuclei. (HX – E, x 400).

**Fig (1 – F)**

Liver section of a mature mouse one month after treatment by toxic mutagen (gp B) showing a blood vessel which appeared invaded by lymphocytes and showed dissociation in their lining walls. Dissociated tumor, atresia in the hepatocytes, binucleated cells and numerous pyknotic nuclei. (Hx – E, X 400 ).

**Fig (1 – G)**

Liver section of a mature mouse one month after mutagen administration (group B) showing congestion, strange dilations and disociation of the walls in the blood vessels and pyknotic nuclei. ( Hx – E, x 400 ).

**Fig (I - H)**

Liver section of a mature treated mouse (group C) one month after treatment by mutagen showing congestion and dilation in the central blood vessel, disociation of the endothelium lining the blood vessel, which appeared invaded by lymphocytes and pyknotic nuclei, atresia in hepatocytes, infiltration by chronic inflammatory cells, aggregation of pyknotic nuclei and vacuolated cytoplasm. (Hx – E x 1000).

**Fig (1 – J)**

Liver section of a mature treated mouse (group C) one month after administration of mutagen showing a healthy lobule with normal arrangement of hepatocytes. (Hx – E, x 400).

**Histochemical results :**

**a.Carbohydrate contents**

**Plate II**

**Fig (2 – A)**

Liver section of a control mouse showing the normal distribution of polysaccharides in controls. (PAS, X 400).



## **ROLE OF FERMENTED MILK IN TREATING THE HISTOPATHOLOGICAL**

### **Fig (2 – B)**

Liver section of a mature mouse (group A) 2 weeks post treatment by mutagen showing an increased amount of polysaccharides comparing with controls and the heterogeneous distribution of polysaccharides. (PAS, X 100)

### **Fig (2 -C)**

Liver section of a mature treated mouse (group B) one month after administration of mutagen showing heterogeneous distribution of polysaccharides in the hepatic gland, congestion and dilations in blood vessels. The – staining quantity was darker than that of controls. (PAS, x 400)

### **Fig (2-D)**

Liver section of a treated mouse (group C) illustrating a marked decrease in the total polysaccharides content in comparison with controls. (PAS, X400).

## **b-Total general Proteins :**

### **Plate III**

#### **Fig (3 – A)**

Liver section of a control mouse showing the normal amount and distribution of total proteins in controls. (B. PH B, X400).

#### **Fig (3 – B)**

Liver section of a mature mouse (group A) 2 weeks post treatment by mutagen showing the amount of total proteins similar or near that of controls (B. PH B x 400).

#### **Fig (3 – C)**

Liver section of a mature treated mouse (group B) one month after administration of mutagen showing increased amount of proteins in the liver tissue comparing with controls. Walls lining the blood vessels and boundaries of hepatocytes appeared darkly stained. (B. PH. B., x 400).

#### **Fig (3 – D)**

Liver section of a mature mouse ( group C ) one month post treatment by mutagen showing severe damage in a carcinogenated area of the hepatic lobule stainability

**AMNAH A. H. RAYES et al.**

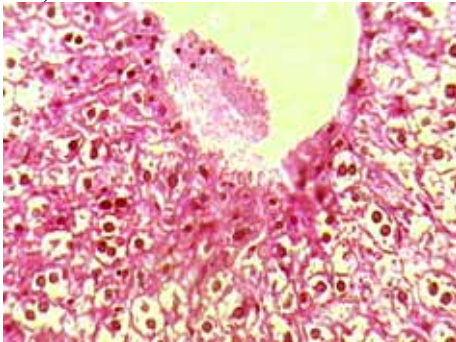
in general was less than that of controls. Some inflammatory patches appeared strongly stained. (B. PH. B, x 400).

**Fig (3 – E)**

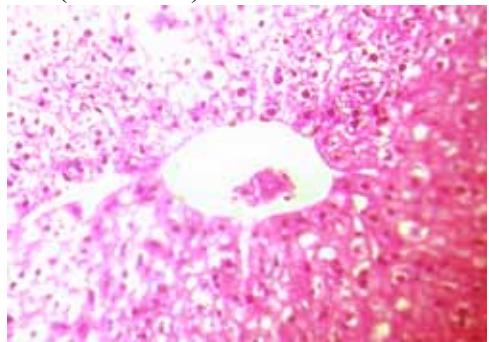
Liver section of a mature treated mouse (group C) one month post treatment by mutagen showing decreased amount of proteins than controls but heterogeneously distributed. The outer surface layers appeared more intensely stained. (B. PH B, x 400)

**PLATE I**

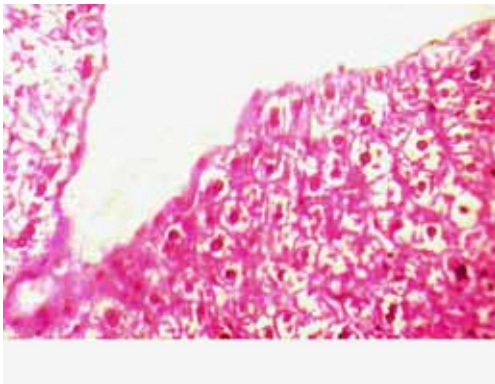
(FIG. 1-A)



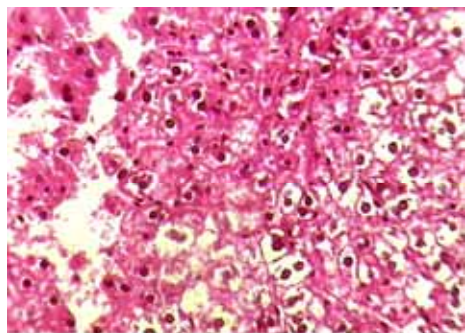
(FIG. 1-B)



(FIG. 1-C)

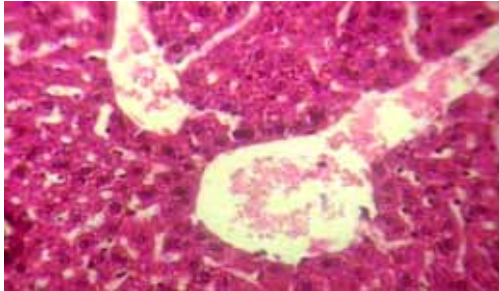


(FIG. 1-D)

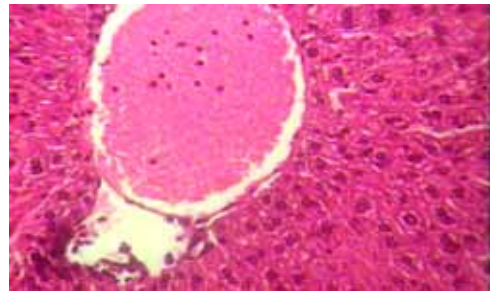


**ROLE OF FERMENTED MILK IN TREATING THE HISTOPATHOLOGICAL**

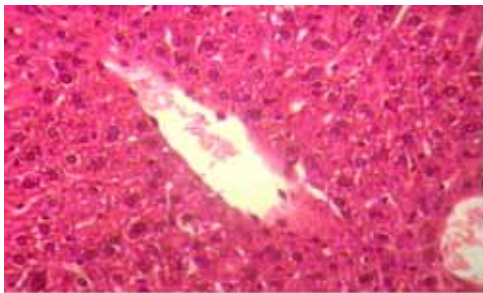
(FIG. 1-E)



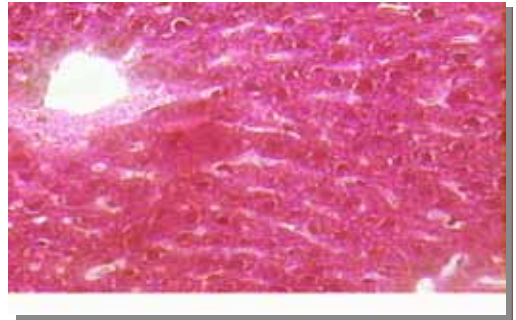
(FIG. 1-F)



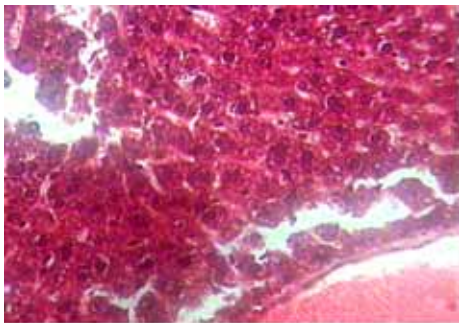
(FIG. 1-G)



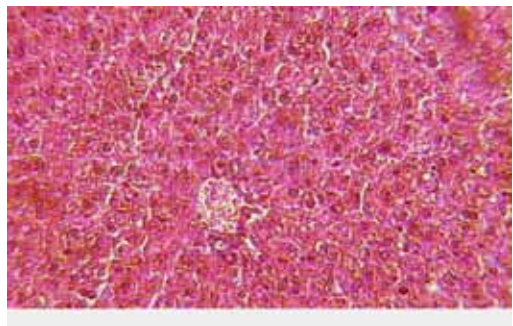
(FIG. 1-H)



(FIG. 1-I)

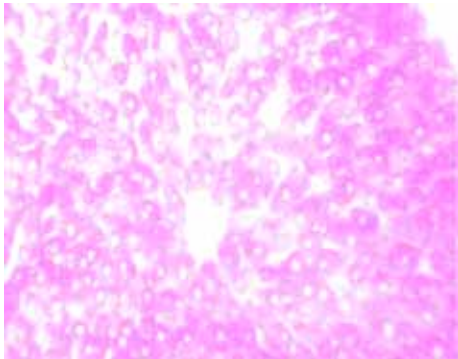


(FIG. 1-J)

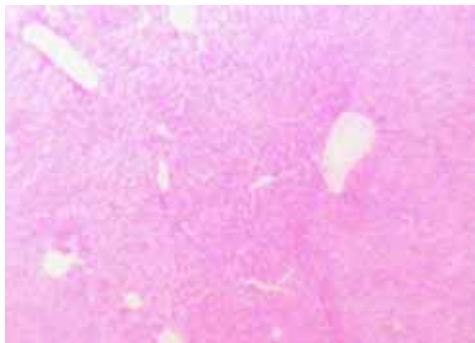


**PLATE II**

(FIG. 2-A )



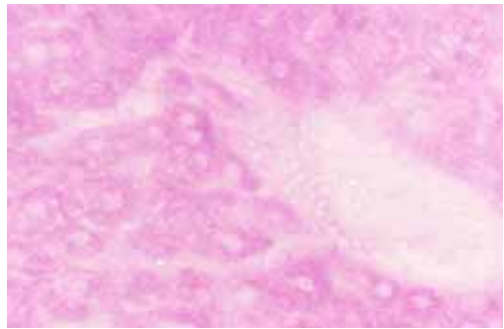
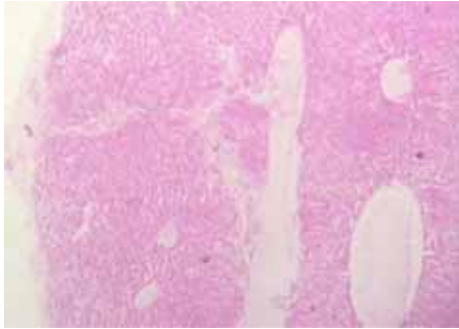
(FIG. 2-B )



(FIG. 2-C )

(FIG. 2-D )

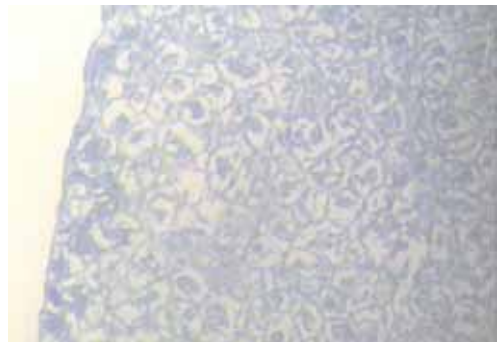
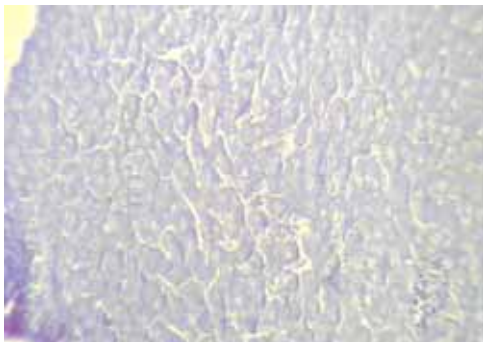
**ROLE OF FERMENTED MILK IN TREATING THE HISTOPATHOLOGICAL**



**PLATE III**

(FIG. 3-A )

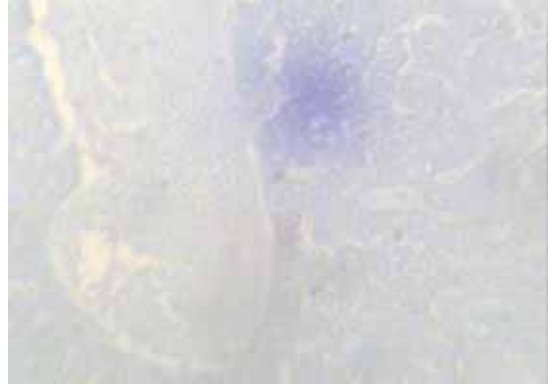
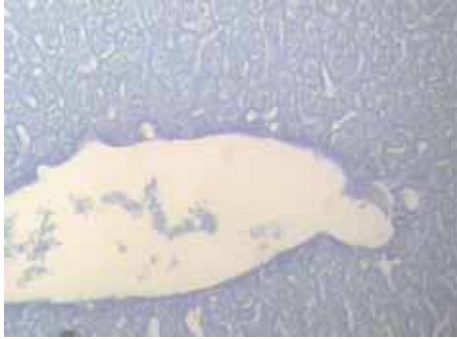
(FIG. 3-B )



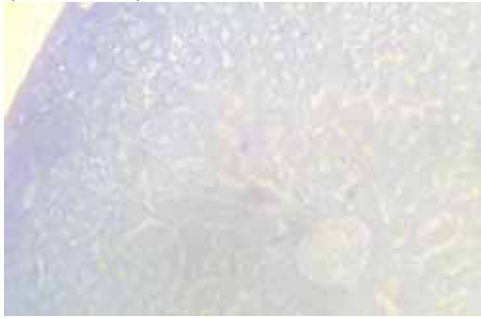
(FIG. 3-C )

(FIG. 3-D )





(FIG. 3-E )



## دور الألبان الطبيعية فى علاج التغيرات المرضية والهستوكيميائية المستحدثة بمادة مسرطنة فى كبد الفئران

\*آمنة اسعد ريس \*\* - نايرة شاكر مهنا

\*قسم الأحياء - كلية العلوم التطبيقية - جامعة ام القرى  
\*\* قسم الألبان - شعبة الصناعات الغذائية والتغذية - المركز القومى للبحوث - مصر

تم اجراء الدراسة الحالية لدراسة التأثيرات الايجابية لتناول الألبان المتخمرة المحتوية على سلالتين من بكتريا البروبيوتك *Bifidobacterium ssp*, *lactobacillas spp* , كمواد غذائية تضاف للغذاء اليومي، وتأكيد مدى امكانية وجود تأثير لهذه البكتيريا يحد من التأثيرات المتلفة للنسيج الكبدي، والمستحدثة باعطاء الفئران مادة مسرطنة مطفرة هي (4,3- pyrido H - 5 - 1 methyl - 3 amino . b)

## ROLE OF FERMENTED MILK IN TREATING THE HISTOPATHOLOGICAL

أجريت التجربة باستخدام عشرين فأر تجارب من الذكور تبلغ أعمارها من ٨ - ١٠ أسابيع ومتوسط أوزانها ٢٠ (+ ٣) جم قسمت الى ٤ مجموعات كل منها تتكون من ٥ فئران المجموعة الأولى مجموعة ضابطة تغذت على علف فئران عادي لمدة ٣٠ يوما ، في حين تم اعطاء المادة المسرطنة عن طريق الفم لفئران المجموعات الثلاث الأخرى (٠,٢٥ جم لكل فأر) في بداية التجربة وتم تغذيتها على غذاء الفئران العادي، وفي اليوم الخامس عشر من بدء التجربة تم تشريح فئران المجموعة A بينما أعطيت فئران المجموعة B حرة ثانية من المادة المسرطنة مكافئة للجرعة الأولى ثم واصلت التغذية على غذاء الفئران العادي لمدة أسبوعين اضافيين، اما فئران المجموعة C فقد أعطيت الجرعة الثانية من المادة المسرطنة في اليوم الخامس عشر و في نفس اليوم بدأت التغذية على الألبان المتخمرة المحتوية على سلالاتي بكتريا البروبيوتك (٣٠ جم لكل فأر يوميا) لمدة اسنوعين اضافيين. تم اجراء عد تصنيفي للبكتريا في البراز كقياس للتنوع الحيوي ، وتم أيضا فحص التغيرات الهستولوجية والهستوكيميائية في تركيب أنسجة الكبد.

وقد أظهرت النتائج أن الفروق في أعداد كل من سلالاتي بكتيريا *Bifidobacterium sp* و *Lactobacillus sp* التأثير الايجابي لتناول الألبان المتخمرة الطبيعية على الفئران، حيث أدت الى تحسن واضح في التركيب الخلوي للكبد كما أدى الى التقليل من التغيرات النسيجية المرضية، كما أظهرت الدراسة الهستوكيميائية نقص طفيف في المحتوى الكلي للكربوهيدرات والبروتينات في كبد فئران المجموعة C بالمقارنة بالمجموعة الضابطة .