

## ANTIOXIDANT ROLE OF ZINC AGAINST THE OXIDATIVE STRESS INDUCED BY CADMIUM AND CHROMIUM IN RATS

Fathy, R. Sleema; Mamdouh, M. Abou El-Magd\* and Alaa, A. Fehaid

\*Department of Forensic Medicine and Toxicology

Faculty of Veterinary Medicine, Mansoura University, Mansoura, Egypt.

### ABSTRACT

To evaluate the role of zinc as antioxidant against the oxidative stress induced by cadmium and chromium, forty two adult male albino rats were divided into seven groups which treated daily for 45 days. First group used as control, second group received 4.4 mg/kg B.wt CdCl<sub>2</sub> by stomach tube, third group received 2.5 mg/kg B.wt sodium dichromate by stomach tube, fourth group received 4.4 mg/kg B.wt CdCl<sub>2</sub> and 2.5 mg/kg B.wt sodium dichromate by stomach tube, fifth group received 4.4 mg/kg B.wt CdCl<sub>2</sub> by stomach tube and ZnCl<sub>2</sub> 300 mg/L drinking water, sixth group received 2.5 mg/kg B.wt sodium dichromate by stomach tube and ZnCl<sub>2</sub> 300 mg/L drinking water, seventh group received 4.4 mg/kg B.wt CdCl<sub>2</sub> and 2.5 mg/kg B.wt sodium dichromate by stomach tube and ZnCl<sub>2</sub> 300 mg/L drinking water. The results revealed that the treatment with cadmium and chromium lead to marked increase in the level of lipid peroxidation (expressed by MDA level), activities of hepatic marker enzymes (AST and ALT) and urea and creatinine concentrations, also lead to decrease in the activities of antioxidant enzymes (SOD, CAT and GPx) and the level of GSH. Histopathological examination revealed degenerative and necrotic changes in liver and kidney. Treatment with zinc significantly reversed the changes induced by cadmium and chromium exposure in all examined parameters.

These results indicate that the alterations caused by cadmium and chromium by generation of reactive oxygen species (ROS) can be decreased by using zinc as antioxidant.

### INTRODUCTION

Cadmium (Cd) is a very toxic heavy metal considered to be a multitarget toxicant and human exposed to it through different industrial products (electroplates, paints, plastics and batteries) and environmental pollution (soil, water, air and food). Exposure to Cd can cause a broad spectrum of toxicological and biochemical dysfunctions in various organs

and tissues depending on the dose, route and duration of exposure (Funakoshi et al., 1995). It was found that cadmium can induce alteration of antioxidant and metabolic status of red blood cells (Kostic et al., 1993), and increases lipid peroxidation (Fucikova et al., 1995).

Chromium (Cr) is a transition metal exists

In various oxidation states but the most predominant states in nature are hexavalent chromium [chromium (VI)] and trivalent chromium [chromium (III)]. Chromium (VI) is commonly used in industrial chrome plating, welding, painting, metal finishes, steel manufacturing, alloy, cast iron and wood treatment (Stohs and Bagchi, 1995). The most important concentration and time dependent effects of hexavalent chromium are increased production of ROS, enhanced excretion of urinary lipid metabolites, lipid peroxidation and apoptotic cell death in both in vitro and in vivo models (Bagchi et al., 2002).

Zinc (Zn) is a trace element essential for cell proliferation and differentiation. It is an important element in preventing free radical formation, in protecting biological structures from damage and in correcting the immune functions (Stefanidou et al., 2008). Under certain conditions, it has antioxidant properties (Powell, 2000) and also zinc is a critical component of biomembranes and is essential for proper membrane structure and function and the activity of numerous enzymes (Bettger and O'Dell, 1981), and plays an important role in regulation of cellular glutathione that is vital to cellular antioxidant defence (Parat, 1997).

This study aimed to evaluate the role of zinc as antioxidant against the oxidative stress induced by cadmium and chromium.

## MATERIAL AND METHODS

### Tested compounds:

Cadmium chloride anhydrous ( $\text{CdCl}_2$ ), Sodium dichromate dihydrate ( $\text{Cr}_2\text{Na}_2\text{O}_7 \cdot 2\text{H}_2\text{O}$ ) and zinc chloride ( $\text{ZnCl}_2$ ) were purchased

from Sigma-Aldrich, Co. (St. Louis, Mo, USA).

### Animals:

Forty two (42) adult male albino rats weighted from 110 to 130 g obtained from experimental Unit, Faculty of Veterinary Medicine, Zagazig University. The animals were apparently clinically healthy. The animals were housed in plastic cages with wood shavings as bedding and kept under controlled condition ( $23 \pm 1^\circ\text{C}$ , 12h light and 12h dark cycle). Rats were fed on standard laboratory pelleted diet and water ad libitum.

### Experimental design:

The experiment was conducted over a period of 45 days, after two weeks period of acclimatization; rats were randomly divided into 7 groups 6 for each. The first group used as control and received normal saline. The second group received daily 4.4 mg/kg B.wt (1/20  $\text{LD}_{50}$ ) anhydrous  $\text{CdCl}_2$  by stomach tube as the oral  $\text{LD}_{50}$  of  $\text{CdCl}_2$  was reported to be 88 mg/kg B.wt according to (USAF, 1990). The third group received daily 2.5 mg/kg B.wt (1/20  $\text{LD}_{50}$ ) sodium dichromate by stomach tube as the oral  $\text{LD}_{50}$  of  $\text{Cr}_2\text{Na}_2\text{O}_7 \cdot 2\text{H}_2\text{O}$  was reported to be 50 mg/kg B.wt according to (Bagchi et al., 1995). The fourth group received daily 4.4 mg/kg B.wt anhydrous  $\text{CdCl}_2$  + 2.5 mg/kg B.wt sodium dichromate by stomach tube. The fifth group received daily 4.4 mg/kg B.wt anhydrous  $\text{CdCl}_2$  by stomach tube +  $\text{ZnCl}_2$  (300 mg/L drinking water) equal to 18 mg/kg B.wt as the therapeutic dose of  $\text{ZnCl}_2$  was reported to be 18 mg/kg B.wt according to (Goel et al., 2005). The sixth group received daily 2.5 mg/kg B.wt sodium dichromate by stomach tube +  $\text{ZnCl}_2$  300 mg/L drinking water. The seventh group

received daily 4.4 mg/kg B.wt anhydrous CdCl<sub>2</sub> + 2.5 mg/kg B.wt sodium dichromate by stomach tube + ZnCl<sub>2</sub> 300 mg/L drinking water.

#### **Samples collection:**

At the end of experiment, blood samples were collected from retro-orbital plexus then serum were separated. For histopathological studies, rats were then sacrificed by decapitation and specimen from liver and kidney were collected and kept in 10% neutral buffered formalin.

#### **Biochemical analysis:**

Serum samples were analyzed for superoxide dismutase (SOD), catalase (CAT), glutathione peroxidase (GPx), reduced glutathione (GSH) and lipid peroxide malondialdehyde (MDA) according to (Maral et al., 1977), (Acbi, 1984), (Paglia and Valentine, 1967), (Beutler et al., 1963) and (Sato, 1978) respectively. Alanine aminotransferase (ALT), aspartate aminotransferase (AST) were determined according to (Reitman and Frankel, 1957). Urea, creatinine and total protein (TP) were determined according to (Patton and Crouch, 1977), (Henry, 1974) and (Young, 2001) respectively.

#### **Histopathological examination:**

Prepared sections of 5 micron thickness from liver and kidney were stained by hematoxyline and eosin (H&E) and examined microscopically according to (Bancroft et al., 1990).

#### **Statistical analysis:**

Data were subjected to statistical analysis using statistical software Program (SPSS for

Windows, version 15, USA).

## **RESULTS & DISCUSSION**

#### **Biochemical analysis:**

The activities of SOD, CAT and GPx were significantly decreased in Cd-, Cr- and Cd+Cr-treated groups in compare to the control group. There were no significant differences between control and groups which received zinc with cadmium and chromium (Fig. 1, 2, 3). GSH levels were significantly decreased in Cd- and Cr-treated groups in compare to the control group and there were no significant differences between control and groups which received zinc with Cd and Cr and also group received Cd+ Cr (Fig. 4). MDA levels were significantly increased in Cd- and Cr-treated groups in compare to the control group and there were no significant differences between control and groups which received zinc with Cd and Cr and also group received Cd + Cr (Fig. 5). These results are shown in table (1).

Total protein levels were significantly decreased in Cd- and Cr-treated groups in compare to the control group and there were no significant differences between control and groups which received zinc with Cd and Cr and also group received Cd+ Cr (fig. 6). ALT and AST levels were significantly increased in Cd- and Cr-treated groups in compare to the control group and there were no significant differences between control and groups which received zinc with Cd and Cr and also group received Cd+ Cr (fig. 7, 8). Urea and creatinine levels were significantly increased in Cd- and Cr-treated groups in compare to the control group and there were no significant differences between control and groups which received

zinc with Cd and Cr and also group received Cd + Cr (fig. 9, 10). These results are shown in table (2).

#### **Histopathological findings:**

In Cd-treated group, liver showed pale eosinophilic translucent material seems to be Amyloid in the dilated hepatic sinusoids resulted in pressure atrophy and necrosis was noticed after 45 days of treatment (fig. 11-A). Kidney showed focal replacement of the renal parenchyma with extravasated blood (hemorrhage) and hyaline cast in some renal tubules with dilatation of the others (fig. 12-A).

In Cr-treated group, liver showed portal hepatitis, newly formed bile ductules and periportal hepatic necrosis besides, pale eosinophilic translucent material was noticed in the hepatic sinusoids seems to be Amyloid (fig. 11-B). Kidney showed massive replacement of the renal parenchyma with extravasated erythrocytes and edema with degenerative changes and necrosis of the renal tubules besides, hyperplasia of glomerular mesangial cells moreover damage and epithelial desquamation of parital layer of the glomerulous was noticed (fig. 12-B).

In Cd+Cr-treated group, dysplasia, subcapsular hepatic necrosis with moderate degeneration and necrosis of the other hepatic parenchyma besides, dilatation and congestion of the hepatic sinusoids (fig. 11-C). Kidney showed mild degenerative changes (cloudy swelling) of some renal tubules.

In Cd+Zn-treated group, liver showed apparently normal hepatic parenchyma (fig. 11-D). Kidney showed mild degenerative and ne-

crotic changes of the renal parenchyma besides congestion and hemorrhage (fig. 12-C). In Cr+Zn-treated group, liver showed apparently normal hepatic parenchyma. Kidney showed mild cloudy swelling of some renal tubules (fig. 12-D). In Cd+Cr+Zn-treated group, mild degenerative changes were observed in liver and kidney.

Superoxide dismutase (SOD), catalase (CAT) and glutathione peroxidase (GPx) constitute a metabolic protection team of defense against reactive oxygen species (ROS) by limiting the effects of oxidant molecules in tissues and acted in the defense against oxidative cell injury by means of being scavengers (Gutteridge, 1995). SOD is a copper and zinc-containing enzyme that catalyses the dismutation of superoxide radicals (McCord et al., 1976). The toxic effect of Cd on SOD activity could result from interactions between Cd and Zn in the SOD molecule (Bauer et al., 1980). Catalase is a heme-containing homotetrameric enzyme which catalyses the reduction of H<sub>2</sub>O<sub>2</sub> to water and oxygen and thus protects the cell from oxidative damage by H<sub>2</sub>O<sub>2</sub> and OH (Kirkman and Gactani., 2007). Glutathion peroxidase plays a major role in the reduction of H<sub>2</sub>O<sub>2</sub> and hydroperoxide to mono toxic products (Bruce et al., 1982). These reports can explain the results of the present study which revealed decrease in the activities of SOD, CAT and GPx in Cd-treated groups by the direct binding of Cd to the active site, if it contains-SH groups (Quig, 1998) or displacement of metal cofactors from active sites of enzymes (Casalino et al., 2000) or by increase the enzymes usage in scavenging free radicals by Cd exposure thus causing irreversible inhibition in the enzymes

activity (Waisberg et al., 2009). GSH is a tripeptide of glutamic acid, cysteine and glycine that occur in approximately 2mM concentrations of RBCs and has a highly reactive (easily oxidized) sulfhydryl (SH) group that may act non enzymatically as a free radical acceptor to counteract oxidant damage (Prins and Loos, 1989). In the present study, decreased GSH levels in Cd-treated group lead to increase the susceptibility to free radical damage which reported by (Renugadevi and Parbu, 2010; Jihan et al., 2011).

Decomposition products of lipid hydroperoxides such as malondialdehyde (MDA) play an important role in Cd-induced toxicity (Renugadevi and Parbu, 2010). The results of the present study revealed significant increase in plasma MDA levels in rats treated with Cd indicating the increase in lipid peroxidation which is agree with (Parl et al., 2007; Borges et al., 2008; Ferramola et al., 2011). (Bagchi et al., 1997) reported an increase in the level of plasma lipid peroxidation expressed by MDA level in rats treated orally with CdCl<sub>2</sub> (4.4 mg/kg B.wt) for 120 days, this increase was observed after 15 days of treatment with maximum elevation occurred between 30-45 days of treatment suggesting the dose and time dependent effect of cadmium where the low dose daily exposure results in cumulative effect which ultimately plateau after sufficient exposure has occurred.

It is well established that cadmium intoxication significantly elevated the serum hepatic marker enzymes ALT and AST (Milton Parbu et al., 2008; Renugadevi and Parbu, 2010). In the present study, there were an increase in plasma AST and ALT activities in

rats treated with cadmium suggested that Cd lead to cellular leakage and loss of functional integrity of hepatic membrane architecture leading to leakage of these enzymes from the liver cytosol into the blood stream which is confirmed by the histopathological examination of liver.

On the other hand, several studies have demonstrated that cadmium induces nephrotoxicity associated with proximal tubular damage (Sabolic et al., 2001; Parl et al., 2007). In the present study, the increases in serum urea and creatinine concentrations agree with (Renugadevi and Parbu, 2009), these results may be attributed to kidney dysfunction which was confirmed by the histopathological examination of kidney. The decrease in plasma total protein in rats treated with cadmium is in agreement with (El-Demerdash et al., 2004) and it may be due to increased excretion of high molecular weight proteins in urine (Christopher., 1991).

Once Cr (VI) enters cell, it is reduced by certain antioxidant molecules such as glutathione (Shi and Dalal 1988) to generate Cr (V) and during the stepwise one-electron reduction of Cr (VI) to the final stable product Cr (III), a whole spectrum of reactive oxygen species (ROS) is generated through the Fenton and Haber-Weiss reaction (O'Brien et al., 2003) which lead to oxidative stress.

Results revealed decrease in the activities of SOD, CAT and GPx, in serum of rats treated with sodium dichromate which may be attributed to the direct binding of chromium to

SOD (Yamakura and Suzuki, 1980), the increase in ROS generation suggested the decreased plasma antioxidant activities (Alkan et al., 1997). These findings are reported by (Soudani et al., 2011).

Lipid peroxidation is one of the main manifestations of oxidative damage, which plays an important role in the toxicity of many xenobiotics as chromium (Anane and Creppy, 2001). The increase in MDA levels in Cr-treated group is in agreement with (Bagchi et al., 1997) who reported that the daily oral administration of 1/20LD<sub>50</sub> of sodium dichromate for 120 days lead to increase in plasma lipid peroxidation in rats and the greater increase were observed between 30-45 days of treatment.

In addition, after oral exposure to hexavalent chromium, transaminases (AST and ALT) were significantly increased in plasma which may be due to oxidative stress and liver damage (Kalayarasan et al., 2008) which confirmed by the histopathological examination of liver.

Plasma levels of urea and creatinine were also significantly increased indicating the renal damage and confirming previous reports of (El-Demerdash et al., 2006; Soudani et al., 2010) which confirmed by the histopathological examination of kidney.

On the other hand, the protective effect of hexavalent chromium on isolated hepatocytes previously exposed to cadmium was reported by (Stacey and Klaassen, 1981). The present study indicated that in Cd+Cr-treated group, there were an antagonizing action between

the two metals which is indicated by the reversing of MDA levels and the activities of antioxidant enzymes. Moreover, chromium not completely prevents the histopathological alterations induced by Cd in liver.

The role of Zn in protecting biological structures from ROS damage may be due to several factors as Zn is known to induce the production of metallothionein (Kagi, 1991), and is an excellent scavenger of •OH (Prasad, 1993), also Zn is an essential structural component of Cu/Zn SOD which is an antioxidant enzyme. Finally, Zn can act as a protective agent for thiols and other chemical groups (Santon et al., 2003). As a result of these mechanisms, Zn supplementation together with Cd administration prevents several of the effects observed when Cd is administered alone. Zinc can also completely reverse the Cr-induced oxidative stress (Rudolf and Cervinka, 2006).

In the present study, the supplementation of ZnCl<sub>2</sub> with cadmium or with chromium reverses all the examined parameters nearly to its normal values. These results are in agreement with (Jemat et al., 2007; Jihen et al., 2009). In addition, Zn can prevent the histopathological alteration induced by Cd in liver and kidney which is in agreement with (Jemat et al., 2010; Rogalska et al., 2011). Moreover, Zn reduced the hepatic and renal damage caused by chromium.

In the present study, zinc act as antioxidant and chromium also antagonize the action of cadmium so, Zn and Cr decrease the Cd-induced elevation in MDA level, serum hepatic enzymes (AST and ALT) and concentra-

tions of urea and creatinine. Moreover, Zn and Cr increase the Cd-induced reduction in the activities of antioxidant enzymes. In addition, the histopathological alterations in hepatic and renal tissues were less marked in

Cd+Cr+Zn-treated group. These results indicate that the treatment of cadmium toxicity by zinc and chromium together is more effective than the treatment with zinc or chromium alone.

Table (1): Biochemical Parameters of rats treated with cadmium, chromium and zinc for 45days (Mean  $\pm$  S.E).

Group	SOD U/ml	CAT U/L	GPx. mU/ml	GSH mg/dl	MDA nmol/ml
Cont.	2003.3 <sup>a</sup> $\pm 157.34$	348.33 <sup>a</sup> $\pm 16.25$	1272.0 <sup>ac</sup> $\pm 38.90$	1.12 <sup>bc</sup> $\pm 0.10$	15.83 <sup>c</sup> $\pm 1.92$
Cd	1002.0 <sup>u</sup> $\pm 61.14$	198.00 <sup>o</sup> $\pm 20.42$	1022.6 <sup>c</sup> $\pm 17.11$	0.46 <sup>o</sup> $\pm 0.20$	30.50 <sup>a</sup> $\pm 3.86$
Cr	1221.1 <sup>c</sup> $\pm 50.72$	203.00 <sup>o</sup> $\pm 43.82$	1042.1 <sup>uc</sup> $\pm 34.31$	0.55 <sup>o</sup> $\pm 0.50$	24.00 <sup>o</sup> $\pm 3.67$
Cd+Cr	1771.0 <sup>o</sup> $\pm 31.24$	251.33 <sup>bc</sup> $\pm 18.54$	1146.0 <sup>oo</sup> $\pm 44.00$	0.90 <sup>c</sup> $\pm 0.01$	12.71 <sup>c</sup> $\pm 0.71$
Cd+Zn	1991.0 <sup>a</sup> $\pm 102.10$	318.00 <sup>bc</sup> $\pm 30.29$	1182.0 <sup>bc</sup> $\pm 103.34$	1.15 <sup>bc</sup> $\pm 1.10$	15.62 <sup>c</sup> $\pm 3.14$
Cr+Zn	2083.6 <sup>a</sup> $\pm 152.06$	351.00 <sup>b</sup> $\pm 31.44$	1188.6 <sup>bc</sup> $\pm 23.72$	1.15 <sup>bc</sup> $\pm 0.06$	14.33 <sup>c</sup> $\pm 1.68$
Cd+Cr+Zn	2057.0 <sup>a</sup> $\pm 101.12$	370.83 <sup>a</sup> $\pm 61.69$	1309.0 <sup>a</sup> $\pm 64.92$	1.24 <sup>a</sup> $\pm 0.19$	16.76 <sup>c</sup> $\pm 2.72$

The means in the same column having the same superscript not significantly different ( $P < 0.05$ ).

Table (2): Biochemical Parameters of rats treated with cadmium, chromium and zinc for 45days (Mean  $\pm$  S.E).

Group	TP g/dl	ALT U/gm	AST U/gm	Urea mg/dl	Creat. mg/dl
Cont.	7.94 <sup>o</sup> $\pm 0.39$	14.13 <sup>bc</sup> $\pm 1.36$	49.50 <sup>o</sup> $\pm 2.56$	28.00 <sup>oa</sup> $\pm 2.04$	0.84 <sup>o</sup> $\pm 0.04$
Cd	5.42 <sup>u</sup> $\pm 0.43$	27.58 <sup>a</sup> $\pm 2.16$	65.00 <sup>a</sup> $\pm 2.69$	50.00 <sup>a</sup> $\pm 2.12$	1.21 <sup>a</sup> $\pm 0.10$
Cr	5.06 <sup>o</sup> $\pm 0.25$	23.50 <sup>a</sup> $\pm 3.39$	67.33 <sup>a</sup> $\pm 2.36$	39.66 <sup>c</sup> $\pm 4.78$	1.22 <sup>a</sup> $\pm 0.19$
Cd+Cr	8.23 <sup>o</sup> $\pm 0.54$	17.75 <sup>b</sup> $\pm 2.55$	50.66 <sup>b</sup> $\pm 2.33$	32.00 <sup>oo</sup> $\pm 1.29$	0.68 <sup>o</sup> $\pm 0.02$
Cd+Zn	8.63 <sup>a</sup> $\pm 0.57$	14.00 <sup>bc</sup> $\pm 1.87$	50.16 <sup>b</sup> $\pm 2.28$	35.00 <sup>oo</sup> $\pm 3.72$	0.79 <sup>o</sup> $\pm 0.03$
Cr+Zn	7.70 <sup>a</sup> $\pm 0.28$	11.23 <sup>c</sup> $\pm 1.28$	51.50 <sup>o</sup> $\pm 3.73$	29.50 <sup>oa</sup> $\pm 3.30$	0.82 <sup>o</sup> $\pm 0.05$
Cd+Cr+Zn	7.69 <sup>a</sup> $\pm 0.32$	16.30 <sup>o</sup> $\pm 2.21$	45.16 <sup>o</sup> $\pm 4.15$	24.50 <sup>o</sup> $\pm 2.23$	0.75 <sup>o</sup> $\pm 0.03$

The means in the same column having the same superscript not significantly different ( $P < 0.05$ ).



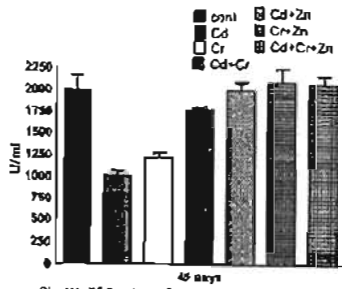


Fig. (1): SOD values of rats treated with Cd, Cr and Zn for 45 days.

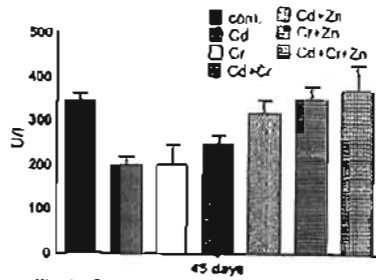


Fig. (2): Catalase values of rats treated with Cd, Cr and Zn for 45 days.

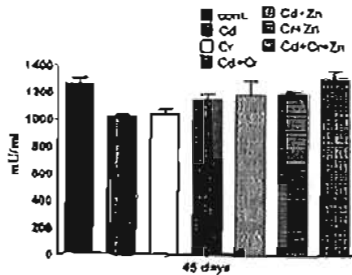


Fig. (3): Glutathione peroxidase values of rats treated with Cd, Cr and Zn for 45 days.

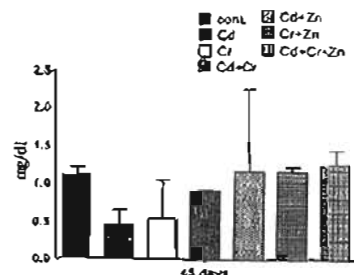


Fig. (4): GSH values of rats treated with Cd, Cr and Zn for 45 days.

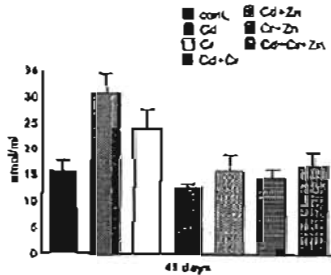


Fig. (5): MDA values of rats treated with Cd, Cr and Zn for 45 days.

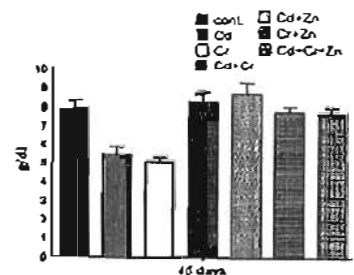


Fig. (6): TP values of rats treated with Cd, Cr and Zn for 45 days.

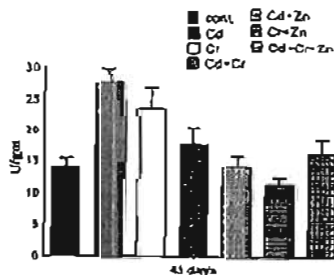


Fig. (7): ALT values of rats treated with Cd, Cr and Zn for 45 days.

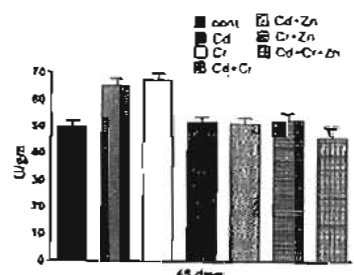


Fig. (8): AST values of rats treated with Cd, Cr and Zn for 45 days.

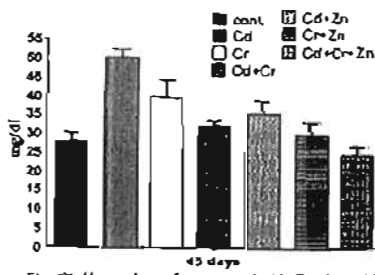


Fig. (9): Urea values of rats treated with Cd, Cr and Zn for 45 days.

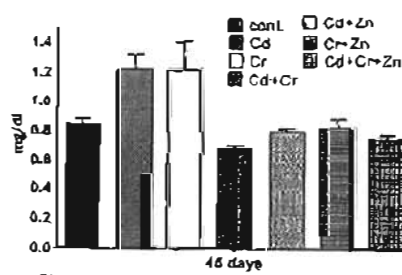
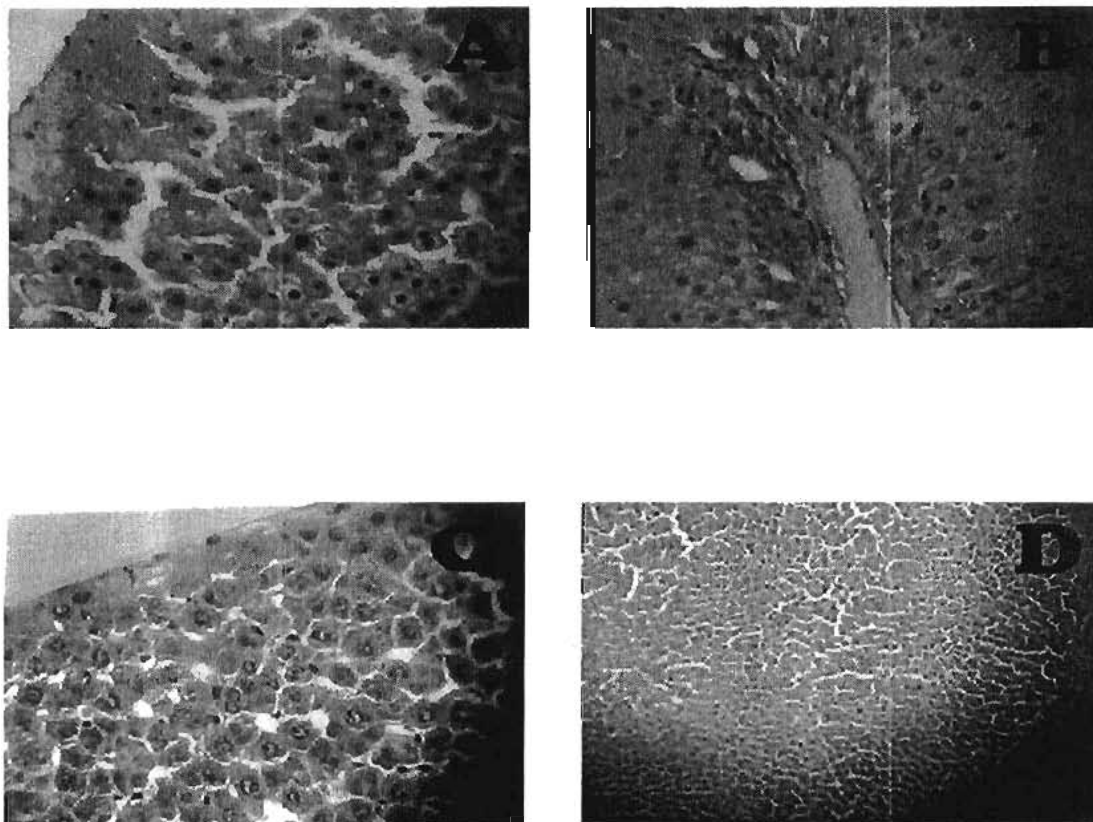
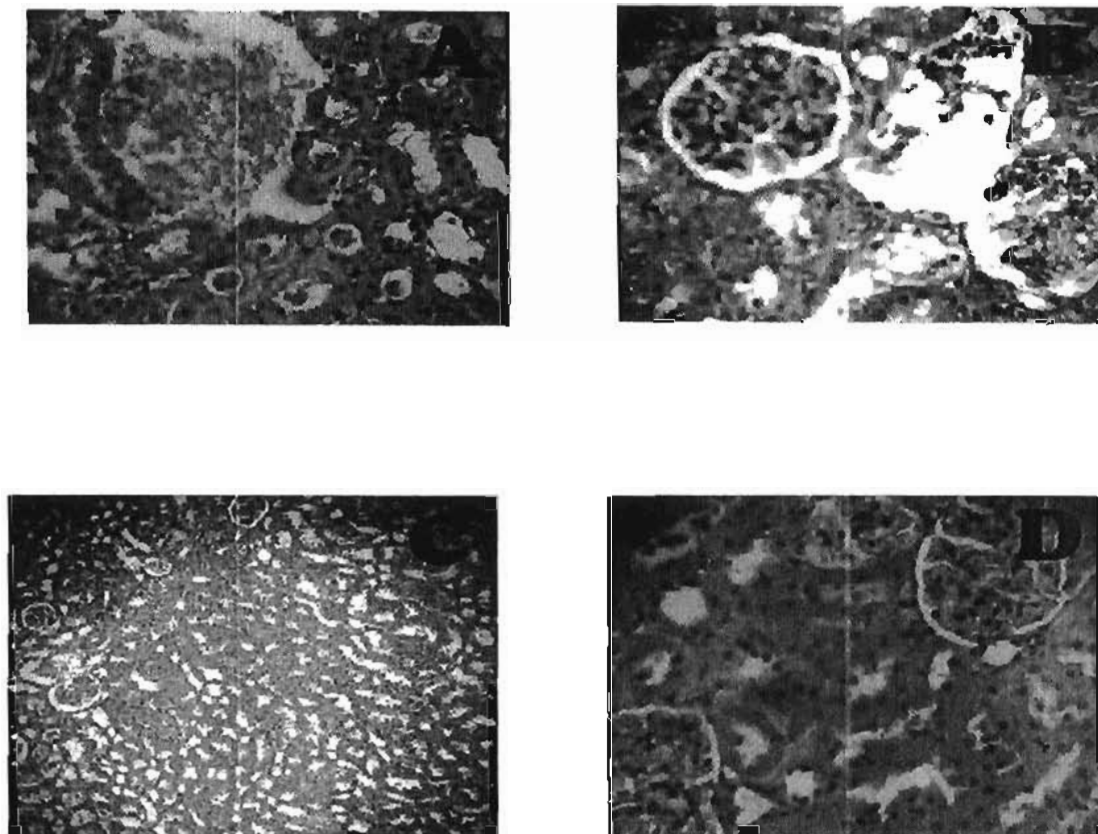


Fig. (10): Creatinine values of rats treated with Cd, Cr and Zn for 45 days.



**Fig. (11):** Histopathology of liver in rats. (A) liver of Cd-treated group shows pale eosinophilic translucent material seems to be Amyloid in the dilated hepatic sinusoids resulted in pressure atrophy and necrosis. (B) liver of Cr-treated group shows portal hepatitis, newly formed bile ductules and periportal hepatic necrosis besides, pale eosinophilic translucent material in the hepatic sinusoids seems to be Amyloid. (C) liver of Cd+Cr-treated group shows dysplasia, subcapsular hepatic necrosis with moderate degeneration and necrosis of the other hepatic parenchyma besides, dilatation and congestion of the hepatic sinusoids. (D) liver of Cd+Zn-treated group shows apparently normal hepatic parenchyma.



**Fig. (12):** Histopathology of kidney of rats. (A) Kidney of Cd-treated group shows focal replacement of the renal parenchyma with extravasated blood and hyaline cast in some renal tubules with dilatation of the others. (B) Kidney of Cr-treated group shows massive replacement of the renal parenchyma with extravasated erythrocytes and edema with degenerative changes and necrosis of the renal tubules besides, hyperplasia of glomerular mesangial cells and epithelial desquamation of parital layer of the glomerulous. (C) Kidney of Cd+Zn-treated group shows mild degenerative and necrotic changes of the renal parenchyma besides congestion and hemorrhage. (D) Kidney of Cr+Zn-treated group shows mild cloudy swelling of some renal tubules.

## REFERENCES

- Aebi, H. (1984)** : Catalase in vitro. *Methods Enzymol.* 105, 121-126.
- Alkan, L.; Simsek, F.; Haklarm, G.; Kervancioglu, E.; Ozveri, H.; Yalcin, S. and Akdas, A. (1997)**: Reactive oxygen species production by spermatozoa of patients with idiopathic infertility: relationship to seminal plasma antioxidants. *J. Urol.* 157: 140-143.
- Ananc, R. and Creppy, E. E. (2001)** : Lipid peroxidation as pathway of aluminum cytotoxicity in human skin fibroblast cultures: prevention by superoxide dismutase and catalase and vitamins E and C. *Hum. Exp. Toxicol.* 20: 477-481.
- Bagchi, D.; Bagchi, M.; Tang, L. and Stohs, S. J. (1997)** : Comparative in vitro and in vivo protein kinase C activation by selected pesticides and transition metal salts. *Toxicol. Lett.* 91, 31-39.
- Bagchi, D.; Balmoori, J.; Bagchi, M.; Ye X., Williams, C. B. and Stohs, S. J. (2002)** : Comparative effects of TCDD, endrin, naphthalene and chromium VI on oxidative stress and tissue damage in the liver and brain tissues of mice. *Toxicology* 175: 73-82.
- Bagchi, D.; Hassoun, E. A.; Bagchi, M.; Muldoon, D. F. and Stohs, S. J. (1995)** : Oxidative stress induced by chronic administration of sodium dichromate (Cr(VI)) to rats. *Comp. Biochem. Physiol.* 110C: 281-287.
- Bancroft, J. P.; Stevens, A. and Turner, D. R. (1990)**: Theory and practice of histological techniques, third edition. Clurechill Livingstone, Edinburgh, London.
- Bauer, R.; Demeter, I.; Hasemann, V. and Johansen, J. T. (1980)** : Structural properties of the zinc site in Cu, Zn-superoxide dismutase; perturbed angular correlation of gamma ray spectroscopy on the Cu, 111Cd-superoxide dismutase derivative. *Biochem Biophys Res Commun* 94:1296-1302.
- Bettger W. J. and O'Dell B. L. (1981)** : A critical physiological role of zinc in the structure and function of biomembranes. *Life Sci.* 28: 1425-1438.
- Beutler, E.; Duron O. and Kelly M. B. (1963)** : *J. lab clin. Med.* 61: 882.
- Borges, L. P.; Brandao, R.; Godoi, B.; Nogueira C. W. and Zeni G. (2008)** : Oral administration of diphenyl diselenide protects against cadmium-induced liver damage in rats. *Chemico-Biological Interactions* 171: 15-25.
- Bruce, A.; Freeman, D. and James C. (1982)**: Biology of disease-free radicals and tissue injury. *Lab Invest.* 47: 412-426.
- Casalino, E.; Calzaretti, G.; Sblano, L. and Landriscina C. (2000)**: Cadmium dependent enzyme activity alteration is not imputable to lipid peroxidation. *Archives of Biochemistry and Biophysics* 383: 288-295.
- Christopher, T. (1991)**: Potential contribution of dietary sources to urinary cadmium and b2-microglobulin excretion of occupationally exposed workers. *Journal of Occupational Medicine* 33: 1175-1179.
- El-Demerdash F. M.; Yousef M. I.; Kedwany, F. S. and Baghdadi, H. H. (2004)**: Cadmium-induced changes in lipid peroxidation, blood hematology, biochemical parameters and semen quality of male rats: protective role of vitamin E and b-carotene. *Food Chem. Toxicol.* 42: 1563-1571.
- El-Demerdash, F. M.; Yousef, M. I. and Elawwad, F. A. (2006)**: Biochemical study on the protective role of folic acid in rabbits treated with chromium (VI). *J Environ Sci Health* 41(5):731-746.

- Ferramola, M. L.; Anton, R. L.; Anzulovich, A. C. and Giménez, M. S. (2011)** : Myocardial oxidative stress following sub-chronic and chronic oral cadmium exposure in rats. *environmental toxicology and pharmacology* 32: 17-26.
- Fucikova, A.; Slamova, A.; Szakova, J.; Cibulka, J. and Heger, J. (1995)**: The influence of dietary cadmium on hematologic parameters and phagocytic activity of leukocytes in rats. *Zivocisna Vyroba* 40: 15.
- Funakoshi, T.; Ohta, O.; Shtmada, H. and Kojima, S. (1995)**: Effects of dithiocarbamates and cadmium on the enzymatic activities in liver, kidney, and blood of mice. *Toxicol. Lett.* 78, 183.
- Goel, A.; Dani, V. and Dhawan, D. K. (2005)**: Protective effects of zinc on lipid peroxidation, antioxidant enzymes and hepatic histoarchitecture in chlorpyrifos-induced toxicity. *Chem Biol Interact.* 156:131-40.
- Gutteridge, J. M. C. (1995)**: Lipid peroxidation and antioxidants as biomarkers of tissue damage. *Clin.Chem.* 41, 1819-1828.
- Henry, R. J.; Common, D. C. and Winkelman, J. W. (1974)**: *Clinical Chemistry Principles and Techniques*. Academic Press. New York. 437-440.
- Jemal, H.; Lachkar, H. A.; Messaoudi, I. and Kerkenia, A. (2010)**: Effects of zinc pretreatment on blood glutathione, serum zinc and kidney histological organisation in male rats exposed to cadmium. *Journal of Trace Elements in Medicine and Biology* 24: 277-282.
- Jemal, H.; Messaoudi, I.; Chaouch A. and Kerkeni, A. (2007)**: Protective effect of zinc supplementation on blood antioxidant defense system in rats exposed to cadmium. *J Trace Elem Med Biol* 21: 269-73.
- Jihen, E. H.; Messaoudi, I.; Fatima, H. and Abdelhamid, K. (2009)**: Protective effects of selenium (Se) and zinc (Zn) on cadmium (Cd) toxicity in the liver of the rat: Effects on the oxidative stress. *Ecotoxicology and Environmental Safety* 72:1559-1564.
- Jihen, E. H.; Sonia, S.; Fatima, H.; Taha, M. S. and Abdelhamid, K. (2011)**: Interrelationships between cadmium, zinc and antioxidants in the liver of the rat exposed orally to relatively high doses of cadmium and zinc. *Ecotoxicol Environ Saf.* Jul 2. (Abstract).
- Kagi J. H. (1991)**: Overview of metallothionein. *Methods Enzymol* 205: 613-26.
- Kalayarasan, S.; Sriram, N.; Suresh Kumar, A. and Sudhandiran, G. (2008)**: Chromium (VI)-induced oxidative stress and apoptosis is reduced by garlic and its derivative S-allylcysteine through the activation of Nrf2 in the hepatocytes of Wistar rats. *J. Appl. Toxicol.* 28(7): 908-19.
- Kirkman H. N. and Gaetani G. F. (2007)**: Mammalian catalase: a venerable enzyme with new mysteries. *Trends Biochem. Sci.* 32, 44 - 50.
- Kostic, M. M.; Ogtjanovic, B.; Dimitrijevic, S.; Zikic, R. V.; Stajin, A. and Rosic, G. L. (1993)**: Cadmium-induced changes of antioxidant and metabolic status in red blood cells of rats: in vivo effects. *Eur J Haematol* 51:86-92.
- Maral, J.; Puget, K. and Michelson, A. M. (1977)**: Comparative study of superoxide dismutase, catalase and glutathione peroxidase levels in erythrocytes of different animals. *Biochem. Biophys. Res. Common.* 77:1525-1535.
- McCord, J. M.; Keele, B. B. and Fridovich, I. (1976)**: An enzyme based theory of obligate anaerobiosis. The physiological functions of superoxide dismutase. *Proc Nat Acad*

Sci USA 68: 1024-1027.

**Milton prabu, S.; Selvarajan, N.; Hemalatha, S. and Ramesh Kumar T. (2008):** Hepatoprotective effect of Andrographis paniculata on cadmium induced toxicity in male wistar rats. *Toxicol Int.* 15: 21-25.

**O'Brien, T. J.; Ceryak, S. and Patterno S. R. (2003):** Complexities of chromium carcinogenesis: role of cellular response, repair and recovery mechanisms. *Mutat Res* 533:3-36.

**Paglia, D. E. and Valentine, W. N. (1967):** *J. Lab. Clin. Med.* 70: 158 - 169.

**Parat, M. O.; Richard, M. J.; Beani, J. C. and Favier A. (1997) :** Involvement of zinc in intracellular oxidant/antioxidant balance, *Biol. Trace Elem. Res.* 60: 187-204.

**Pari, L.; Murugavel, P.; Sitasawad, S. L. and Sandeep-Kumar K. (2007):** Cytoprotective and antioxidant role of diallyl tetrasulfide on cadmium induced renal injury. An in vivo and in vitro study. *Life Sci.* 80: 650-658.

**Patton, C. J. and Crouch, S. R. (1977):** *Anal. Chem.* 49: 464 - 469.

**Powell, S. R. (2000) :** The antioxidant properties of zinc, *J. Nutr.* 130: 1447S-1454S.

**Prasad, A. S. (1993):** Zinc and enzymes, In: A.S. Prasad (Ed.), *Biochemistry of Zinc*, Plenum Press, New York, pp. 17-53.

**Prins, H. K. and Loos, J. A. (1969):** Glutathione. In "Biochemical Methods in Red Cell Genetics" (J. J. Yunis, Ed.), pp. 1 - 49. Academic Press, New York.

**Quig, D. (1998):** Cysteine metabolism and metal toxicity. *Alternative Medicine Review* 3: 262-270.

**Reitman, S. and Frankel, S. (1957):** Transaminase in serum. *Smer. J. Clin. Path.* 25-56.

**Renugadevi, J. and Prabu, S. M. (2010):** Cadmium-induced hepatotoxicity in rats and

the protective effect of naringenin. *Experimental and Toxicologic Pathology* 62: 171-181.

**Renugadevi, J. and Prabu, S. M. (2009):** Naringenin protects against cadmium-induced oxidative renal dysfunction in rats. *Toxicology* 256: 128-134.

**Rogalska, J.; Pilat-Marcinkiewicz, B. and Brzóška, M. M. (2011) :** Protective effect of zinc against cadmium hepatotoxicity depends on this bioelement intake and level of cadmium exposure: A study in a rat model. *Chem. Biol. Interact.* May 24 (abstract).

**Rudolf, E. and Cervinka, M. (2006) :** The role of intracellular zinc in chromium (VI)-induced oxidative stress, DNA damage and apoptosis. *Chemico-Biological Interactions* 162: 212-227.

**Sabolic, I.; Herak-Kramberger, C. M. and Brow, D. (2001):** Subchronic cadmium treatment affects the abundance and arrangement of cytoskeletal proteins in rat renal proximal tubule cells. *Toxicology* 165: 205-216.

**Santon, A.; Irato, P.; Medici, V.; D'Inca, R.; Albergoni, V. and Sturmiolo, G. C. (2003):** Effect and possible role of Zn treatment in LEC rats, an animal model of Wilson's disease. *Biochem Biophys Acta.* 1637: 91-97.

**Satoh, K. (1978):** *Clinical chemical Acta.* 90: 37.

**Shi, K. and Dalal, N. S. (1988):** On the mechanism of the chromate reduction by glutathione: ESR evidence for the glutathionyl radical and an isolable Cr (V) intermediate. *Biochem Biophys Res Commun* 156:137-142.

**Soudani, N.; Ben Amara, I.; Troudi, A.; Hakim, A.; Bouariz, H.; Ayadi Makni, F.; Zeghal, K. M. and Zeghal, N. (2011):** Oxidative damage induced by chromium (VI) in rat erythrocytes: protective effect of selenium. *J.*

Physiol Biochem. June 11 (Abstract).

**Soudani, N.; Sefi, M.; Amara, I. B.; Boudawara, T. and Zeghal, N. (2010):** Protective effects of Selenium (Se) on Chromium (VI) induced nephrotoxicity in adult rats. *Ecotoxicology and Environmental Safety* 73: 671-678.

**Stacey, N. H. and Klaassen, C. D. (1981) :** Interaction of metal ions with cadmium-induced cellular toxicity. *J Toxicol Environ Health* 7(1):149-58.

**Stefanidou, M.; Maravelias, C.; Dona, A. and Spiliopoulou, C. (2006):** Zinc: a multi-purpose trace element. *Arch. Toxicol.* 80: 1-9.

**Stohs S. J. and Bagchi D. (1995):** Oxidative mechanisms in the toxicity of metal ions. *Free Radic. Biol. Med.* 18:321-336.

**USAF (1990):** Cadmium. In: Installation Restoration Program Toxicology Guide, vol. 5. Harry G. Armstrong Aerospace Medical Research Laboratory, Wright Patterson AFB, OH. system. *Environmental Toxicology and Pharmacology* 24: 160-166.

**Watsberg, M.; Joseph, P.; Hale, B. and Beyersmann, D. (2003) :** Molecular mechanisms of cadmium carcinogenesis. *Toxicology* 192: 95-117.

**Yamakura, F. and Suzuki, K. (1980):** Cadmium and manganese replacement for iron in iron superoxide dismutase from *Pseudomonas ovalis*. *J. Biol. Chem.* 88: 91-96.

**Young D. S. (2001) :** Effect of Disease on Clinical Lab. Test. 4th ed, AACCC Press.

## الملخص العربى

## دور الزنك كمضاد للاكسدة الناتجة عن التسمم بالكادميوم والكروميوم فى الفئران

فتحى رضوان سليم محمد محمد ابوالمجد آلاء أحمد فهيد

جامعة المنصورة - كلية الطب البيطرى - قسم الطب الشرعى والسوم

أستهدفت الدراسة تقييم دور الزنك كمضاد للاكسدة الناتجة عن التسمم بالكادميوم والكروميوم . اجريت الدراسة على عدد ٤٢ من ذكور الفئران البيضاء . قسمت الى ٧ مجموعات تم تجريعها يوميا لمدة ٤٥ يوم . المجموعة الأولى كانت ضابطة والمجموعة الثانية تم اعطائها كلوريد الكادميوم (٤ . ٤ مجم/كجم من وزن الجسم ) باستخدام انبوية اللى المعدى والمجموعة الثالثة تم اعطائها ثنائى كرومات الصوديوم (٥ . ٢ مجم/كجم من وزن الجسم) باستخدام انبوية اللى المعدى والمجموعة الرابعة تم اعطائها كلوريد الكادميوم (٤ . ٤ مجم/كجم من وزن الجسم) وثنائى كرومات الصوديوم (٥ . ٢ مجم/كجم من وزن الجسم ) باستخدام انبوية اللى المعدى والمجموعة الخامسة تم اعطائها كلوريد الكادميوم (٤ . ٤ مجم/كجم من وزن الجسم ) باستخدام انبوية اللى المعدى وكلوريد الزنك (٣٠٠ مجم/ لتر من مياء الشرب) والمجموعة السادسة تم اعطائها ثنائى كرومات الصوديوم (٥ . ٢ مجم/كجم من وزن الجسم ) باستخدام انبوية اللى المعدى وكلوريد الزنك (٣٠٠ مجم/ لتر من مياء الشرب) والمجموعة السابعة تم اعطائها كلوريد الكادميوم (٤ . ٤ مجم/كجم من وزن الجسم ) و ثنائى كرومات الصوديوم (٥ . ٢ مجم/كجم من وزن الجسم ) باستخدام انبوية اللى المعدى بالاضافة الى كلوريد الزنك (٣٠٠ مجم/ لتر من مياء الشرب). وقد اثبتت النتائج ان المعالجة بالكادميوم والكروميوم تؤدى الى زيادة ملحوظة فى معدل اكسدة الدهون (معيبرا عنها بالمالونداى الدهيد) وانشطة انزيمات الكبد ونسب اليوريا والكرياتينين وكذلك تؤدى الى نقص ملحوظ فى أنشطة الانزيمات المضادة للاكسدة (سوبر اكسيد ديسميوتيز، كاتاليز، جلوتاثيون بيروكسيديز) وكذلك معدل الجلوتاثيون المختزل. ولقد اثبتت نتائج الدراسات الهستوباثولوجية وجود تغيرات مرضية فى كلا من الكبد والكلى فى المجموعات المعالجة بالكادميوم والكروميوم. ولكن فى المجموعات المعالجة بالزنك كانت جميع القياسات فى معدلاتها الطبيعية.

وبهذه النتائج اثبتت الدراسة ان الاكسدة الناتجة عن التسمم بالكادميوم والكروميوم يمكن علاجها باستخدام الزنك كمضاد للاكسدة.