

## Combination Therapy with Quercetin and 5-Fluorouracil Ameliorates 1,2-Dimethylhydrazine Induced Carcinogenesis in the Colon of Wistar Rats

Bakheet E. M. Elsadek<sup>1</sup>, Mohamed A. Abdel Aziz<sup>1</sup>, Sahar E. M. El-Deek<sup>2\*</sup>, Mohamed M. M. Mahdy<sup>1</sup>, Mahmoud R. Hussein<sup>3</sup>

<sup>1</sup>Department of Biochemistry, Faculty of Pharmacy, Al-Azhar University, Assiut Branch, P.O. Box No. 71524 Assiut, Egypt.

<sup>2</sup>Department of Medical Biochemistry, Faculty of Medicine, Assiut University, P.O. Box No. 71526, Assiut, Egypt

<sup>3</sup>Department of Pathology, Faculty of Medicine, Assiut University, P.O. Box No. 71526, Assiut, Egypt

### Abstract

**Background:** Colorectal carcinoma (CRC) is a common cause of cancer-related death worldwide. 5-fluorouracil (5-FU), a first-line chemotherapeutic drug in CRC, has several side effects limiting its therapeutic outcomes. Quercetin (QU) is a dietary bioflavonoid with antioxidant and cytotoxic prooxidant properties. Here, we hypothesize that combination treatment with QU and 5-FU can modulate 1,2-dimethylhydrazine (DMH) induced histological and biochemical changes in the colon of Wistar rats. **Methods:** A Wistar rats CRC model was established and the animals were randomly divided into five groups. Rats in group A received a suspending vehicle. Group B rats received DMH twice a week subcutaneously for 4 weeks. Animals in the other groups (C, D and E) received the same treatment of DMH, along with QU or 5-FU (individually) or combined QU+5-FU treatment. **Results:** The DMH-treated rats developed adverse histological alterations (aberrant crypt foci, ACF) and biochemical changes (elevated serum CA19-9; reduced tissue levels of enzymatic antioxidants; elevated CDH12 protein expression and decreased SOX7 mRNA levels). Treatment of DMH-treated animals with QU+5-FU (but not with QU or 5-FU, individually) significantly reversed these changes (i.e., suppressed the formation of ACF; decreased the CA19-9 levels; reduced CDH12 protein expression and increased SOX7 mRNA expression). **Conclusions:** Conclusively, to the best of our knowledge, our study was the first to evaluate the effects of QU+5-FU treatment on the histological and molecular changes following DMH administration in a rat colon model. Our data suggest that combination therapy with QU+5-FU has therapeutic benefits in colon cancer induced by DMH, with potential for translation to spontaneous disease.

### Keywords

5-fluorouracil

CDH12

Colorectal carcinoma

Dimethylhydrazine

Quercetin

SOX7

**Corresponding author: Dr. Sahar EM EL-Deek**, Departments of Medical Biochemistry, Faculty of Medicine, Assiut University, Assiut, Egypt .POX: 71256 Fax: +2-08823337878, Tel: 020/01004419975, Email: aaasahar123@yahoo.com, Sahareldeek\_123@yahoo.com.

## Introduction

Colorectal carcinoma (CRC) is the third most common cancer and the cause of cancer-related death with about one million new annually diagnosed cases worldwide [1]. The pathogenesis of CRC is characterized by gradual accumulation of multiple genetic changes [2]. Experimental model of CRC induced by 1,2-dimethylhydrazine (DMH) in rat colon is morphologically similar to human CRC and is therefore ideal for evaluating therapeutic trials [3]. Histologically, aberrant crypt foci (ACF, including both hyperplastic and dysplastic types) represent the earliest histological changes induced by colon specific carcinogenic agents in rat. ACF share many histological, biochemical and mutational (K-ras and APC genes) changes with colorectal adenomas, dysplasia and carcinomas and as such ACF are considered as putative preneoplastic lesions [4].

CA19-9 is a tumor associated antigen that plays an important role in the adhesion of cancer cells to the vascular endothelial lining. It was initially isolated as a CRC related antigen and is currently used as a tumor marker in the gastrointestinal cancers [5]. Elevated serum CA19-9 levels are associated with a higher frequency of metastasis and lower survival rates, i.e. an adverse prognostic factor in CRC [6]. Cadherins proteins are widely expressed in all living organisms. They play important roles in the formation and maintenance of normal tissue architecture. In tumorigenesis, cadherins contribute to the cell-cell interactions. CDH12 gene encodes CDH12 protein (also known as Br-cadherin) which represents a type II classical cadherin transmembrane glycoprotein responsible for calcium dependent cell-cell adhesion. In

normal tissues, CDH12 protein is involved in the maintenance of tissues structure and morphogenesis [7]. In tumorigenesis, CDH12 is implicated in the development of breast, esophageal, prostate and gastric carcinomas [8, 9]. Interestingly, CDH12 can promote the migration and invasion of the neoplastic cells in the adenoid cystic carcinomas [10].

SOX7, is a member of SOX group F subfamily that possesses strong homolog with the high-mobility group (HMG box). It encodes an HMG box transcription factor involved in the parietal endoderm differentiation [11]. Moreover, SOX7 can regulate vascular endothelial cadherin expression during hematopoietic development and is implicated in human cancers [12].

5-fluorouracil (5-FU) is the traditional chemotherapeutic agent for CRC. Its use is associated with the development of drug resistance and systemic toxicities [13]. Therefore, improving the therapeutic efficacy of 5-FU by its combining with other drugs is a keystone in the treatment of CRC. The rationale behind combination therapy is based on the fact that resistance occurs in a heterogeneous cancer cell population to any single agent could be overwhelmed by using multiple agents with different mechanisms of action [14]. An example for this combination therapy is the use of 5-FU and minimally toxic bioactive substances derived from certain plants [13].

Several plants represent an effective source of bioactive molecules, where the flavonoid scaffold is a central group. This moiety is widely present in fruits, vegetables, tea and certain spices, and is associated with several health benefits due to its radical quenching properties [15].

Flavonoids are potential chemo-preventive and chemo-therapeutic agents [16]. A promising candidate is Quercetin (QU) which represents one of the most abundant dietary flavonoids. QU is typically found in onion, broccoli, and apples [17]. It has a wide spectrum of pharmacological actions including antioxidant, cytotoxic prooxidant, antiinflammatory, antiviral, and antiallergenic activities [18]. More importantly, QU has antiproliferative and anticarcinogenic potentials through hindrance of cell growth, induction of G2/M cell-cycle arrest, inhibition of epidermal growth factor receptor signaling pathway and promotion of apoptosis [19, 20].

The combination treatment of QU and doxorubicin provides a novel therapeutic regimen in breast cancer [16]. In the light of these findings, here we hypothesize that “combination treatment with QU and 5-FU can modulate 1,2-dimethylhydrazine (DMH) induced histological and biochemical changes in the colon of Wistar rats”.

To date, and to the best of our knowledge, studies that evaluate the effects of combination treatment (DMH+QU+5-FU) versus individual therapy (DMH+5-FU or DMH+QU) on the histological and molecular changes in DMH-treated rat colon model are lacking. We carried out this work to test our hypothesis and to address these issues.

## Materials and methods

### Chemicals:

Dimethylhydrazine and QU were purchased from Sigma-Aldrich GmbH (Munich, Germany). Commercially available 5-FU ampoules (250 mg fluorouracil) were purchased from EBEWE

pharma GmbH (Unterach, Austria). CA19-9 rat specific enzyme-linked immune-sorbent assay (ELISA) kit was purchased from Chongqing Biospes Co., Ltd, (Chongqing, China). Rabbit polyclonal anti-CDH12 and alkaline phosphatase-conjugated goat anti-rabbit secondary antibodies were purchased from Novus Biologicals, LLC, Littleton (CO, USA). Mouse monoclonal anti- $\beta$ -actin antibody was purchased from Santa Cruz Biotechnology, Inc. (CA, USA). Total RNA purification kit was purchased from Jena Bioscience GmbH (Jena, Germany). RevertAid M-MuL V Reverse Transcriptase kit was purchased from Thermo Fisher Scientific Inc. (MA, USA). Protease inhibitor cocktail was purchased from Cell Signaling Technology, Inc. (MA, USA). 5-Bromo-4-chloro-3-indolyl phosphate/Nitroblue tetrazolium (BCIP/NBT) substrate detection kit was purchased from Genemed Biotechnologies, Inc. (CA, USA). Molecular screening agarose powder was purchased from Roche Diagnostics, GmbH (Mannheim, Germany). PCR primers were custom-made by Vivantis Technologies Sdn. Bhd. (Selangor Darul Ehsan, Malaysia) to amplify the rat SOX7 and  $\beta$ -actin cDNA (Table 1). All other chemicals, reagents, and solvents (of analytical grade) were obtained from standard suppliers and were used without further purification.

### Animals and experimental design

The experiments were performed after approval of the Institutional Animal Care and Use Committee of the Faculty of Medicine, Assiut University, Assiut, Egypt (IRB606/15/05/2014). All experiments were performed using 13-14 week old healthy male Wistar rats (weighing 140-160 g).

**Table 1:** The SOX7 and  $\beta$ -actin primers used for amplification in RT-PCR detection

Gene	Primer sequence	Amplicon size (bp)	Annealing temp. °C	Gen bank accession number
SOX7	<b>Sense:</b> 5'-CAC CTA GTA CCC TTC ACT GC-3'	366	53	NM_001106045.1
	<b>Anti-sense:</b> 5'-TGG TCT CTG TAG GGC CTG TT-3'			
$\beta$ -actin	<b>Sense:</b> 5'-CCA CCA TGT ACC CAG GCA TT-3	243	55	NM_031144.3
	<b>Anti-sense:</b> 5'-ACG CAG CTC AGT AAC AGT CC-3'			

The animals were purchased from the laboratory animal colony, Assiut University, Assiut, Egypt.

Rats were housed (5 per cage) in wire-floored cages at a regulated environment (temperature,  $22 \pm 2^\circ\text{C}$ ; humidity,  $50 \pm 5\%$ ; night/day cycle, 12 hours) with free access to standard pellet diet and tap water ad libitum. Animals' weights were recorded regularly two times per week and animal behavior and status (general well-being, lethargy and weight gain) were daily monitored. After two weeks acclimatization period, a total of 50 rats were randomly divided into five groups (10 animals each). Dosages for treatment were chosen based on previous studies [3, 14, 21, 22]. Animals in Group A (designated as normal controls) received a suspending vehicle that consisted of 0.5% sodium carboxymethyl cellulose (daily by oral gavages) throughout the experimental period. Group B rats received DMH dissolved in 1 mM EDTA solution pH 6.5, at the dose of 20 mg/kg, subcutaneously in the groin twice weekly for four consecutive weeks to initiate colon carcinogenesis [3], along with the above mentioned suspending vehicle (daily by oral gavages) throughout the experimental period. Animals in the other groups received the same treatment of DMH as in group B, along with QU (Group C: daily QU by oral gavages, 100 mg/kg, suspended in the above

mentioned suspending vehicle for four weeks) [21]; 5-FU (Group D: 4 cycles of 5-FU (100 mg/kg, i.v., weekly via tail vein) [14]; or both QU+5-FU (Group E: in the same above described doses and schedule).

One week after the last treatment, blood samples were collected from all animals via retro-orbital vein plexus for serum preparation following centrifugation at 3500 rpm for 15 minutes at  $4^\circ\text{C}$  using a cooling centrifuge (Beckman model L3-50, USA) that was stored at  $-20^\circ\text{C}$  till time of assays. Animals were then sacrificed by cervical decapitation under isoflurane anesthesia.

Immediately after terminations of the animals, the colons were excised, flushed with ice-phosphate buffered saline, opened longitudinally and the mucosal surface was examined for gross changes. The colonic tissue was divided into four equal parts, and all the proximal sections were stored for the same analysis. The first part was fixed in 10% neutral buffered formalin solution for histopathological examination. The second part was homogenized in ice-cooled phosphate buffered saline using Potter-Elvehjem rotor-stator homogenizer (glass/Teflon homogenizer), fitted with a Teflon pestle (Omni International, Kennesaw, GA, USA) and then stored at  $-70^\circ\text{C}$  for subsequent biochemical assays. The third and

fourth parts were instantly flash frozen in liquid nitrogen and stored separately at  $-70^{\circ}\text{C}$  for subsequent Western blot and RT-PCR assays.

#### **Pathological examinations:**

For pathological examination, the specimens were fixed flat between filter papers in 10% neutral buffered formalin according to standard protocol [23]. Histological examination was performed and the microscopic findings including ACF were identified following sets of criteria described by other groups [24, 25]. As compared to the normal crypts, ACF are characterized by their darker staining (due to nuclear enlargement and mucin depletion) and larger size, elliptical shape, thicker epithelial lining, and larger pericryptal zone. ACF includes hyperplastic and dysplastic types. Hyperplastic ACF consists of elongated occasionally branching crypts with scant mitotic activity (limited to the lower two-third of the crypts) and partial mucin depletion. The nuclei are enlarged and focally crowded. Dysplastic ACF show architectural, (enlarged crypts with dilated lumens and some tortuosity) and cytological (nuclear crowding, enlargement, hyperchromasia, prominent nucleoli, loss of polarity, mucin depletion and mitotic activity) features of dysplasia [24, 25].

#### **Biochemical estimations:**

The analyses (biochemical estimations, Western blot and reverse transcriptase PCR) were replicated on same samples or tissues from other animals in the same group to assure reproducibility of the results. Quantitative estimation of serum CA19-9 levels was achieved using rat specific Sandwich-ELISA Technology kit (Catalog #

BYEK2016) according to the manufacturer's instructions. Lipid peroxidation was determined spectrophotometrically at 535 and 520 nm in the colonic tissue homogenates as thiobarbituric acid reacting substance (TBARS) and is expressed as equivalents of malondialdehyde (MDA) [26]. Results were expressed as nmol/g tissue. Reduced glutathione (GSH) was assayed spectrophotometrically in the colonic tissue homogenates using Ellman assay method on the basis of the reaction of 5,5-dithiobis- (2-nitrobenzoic acid) which is readily reduced by sulfhydryls forming a yellow substance which is measured at 412 nm [27]. Results were expressed as  $\mu\text{mol/g}$  tissue. Superoxide dismutase (SOD) activity in the colonic tissue homogenates was assayed using kinetic procedures that based on the ability of SOD to inhibit the autooxidation of pyrogallol at alkaline pH (8.2) [28]. The enzymatic activity is expressed as U/mg protein. One unit is equivalent to the amount of SOD required to inhibit 50% of pyrogallol autooxidation. Nitric oxide (NO) was assayed spectrophotometrically in the colonic tissue homogenates by measuring its stable metabolites, in particular, nitrite (NO<sub>2</sub>) and nitrate (NO<sub>3</sub>). Quantification of NO<sub>2</sub> and NO<sub>3</sub> was based on the Griess reaction, in which a chromophore with a strong absorbance at 545 nm is formed by reaction of NO<sub>2</sub> with a mixture of naphthylethylenediamine and sulfanilamide [29]. Results were expressed as  $\mu\text{mol/g}$  tissue.

#### **Investigation of CDH12 expression by Western blot technique:**

The colonic tissue homogenates were prepared in ice-cold Tris-HCl lysis buffer, pH 7.4 containing 1% protease inhibitor cocktail using Potter-

Elvehjem rotor-stator homogenizer. Total proteins in each corresponding homogenates were denatured at 95°C for minutes in 2x Laemmli buffer. SDS-PAGE electrophoreses were achieved by loading 50 µg protein per lane at 50 volts through stacking gel following by 125 volts through the resolving gel 12.5% during approximately 2 hours and transferred to a polyvinylidene difluoride (PVDF) membrane using T-77 ECL semidry transfer unit (Amersham Biosciences UK Ltd) for 2 hours. Immunoblotting was performed by incubating the PVDF membrane in TBS buffer containing 0.1% tween-20 and 5% nonfat milk for one hour at 4°C, followed by overnight incubation at 4°C with rabbit polyclonal anti-CDH12 antibody at a dilution of 1:1500. After being washed three times with TBST buffer, each membrane was incubated for one hour at room temperature with an alkaline phosphatase-conjugated goat anti-rabbit secondary antibody at a dilution of 1:5000. After being washed four times in TBST, the membrane bound antibody was detected with a commercially available BCIP/NBT substrate detection kit. Equivalent protein loading for each lane was confirmed by stripping and re-blotting each membrane at 4°C against mouse monoclonal anti-β-actin antibody at a dilution of 1:5000. Quantification of the analysis was further performed using Image J software and expressed as a β-actin ratio.

#### **Detection of SOX7 mRNA using reverse transcriptase PCR (RT-PCR):**

In order to obtain a maximum intact RNA yield, a part of the colonic tissue was harvested in a specific lysis buffer supplied in total RNA purification kit using a Potter-Elvehjem rotor-

stator homogenizer, according to the manufacturer's instruction. To avoid RNA destruction during or after procedure by active RNAses, outer stationary glass tube and inner turning Teflon shaft of the homogenizer were washed with 0.1% diethylpyrocarbonate-treated water (DEPC-treated water), incubated over night at 37°C, and then autoclaved for 15 minutes to eliminate residual DEPC. The purity (A260/A280 ratio) and the concentration of the isolated RNA were determined using a GeneQuant 1300 spectrophotometer (Uppsala, Sweden). RNA quality was subsequently confirmed by gel electrophoresis. Then the first-stand cDNA was synthesized from 4 µg of total RNA using an Oligo(dT) 18 primer and RevertAid M-MuL V Reverse Transcriptase kit. This mixture was incubated at 42°C for one hour, followed by incubation at 70°C for 5 minutes to terminate the reaction. The resulting cDNA was amplified by PCR. In brief, cDNA was first denatured for 3 minutes at 95°C then amplified for 33 cycles consisting of: denaturing for 30 second at 95°C; annealing for 30 second at 53°C; primer extension for 30 second at 72°C followed by one cycle of primer extension for 5 minutes at 72°C. RT-PCR of β-actin was performed in parallel as an internal control with annealing for 30 second at 55°C. The RT-PCR products were analyzed by electrophoresis using 2% molecular screening agarose gel, stained with ethidium bromide and visualized by UV light. Quantification of gel analysis was further performed using Image J software and expressed as a β-actin ratio.

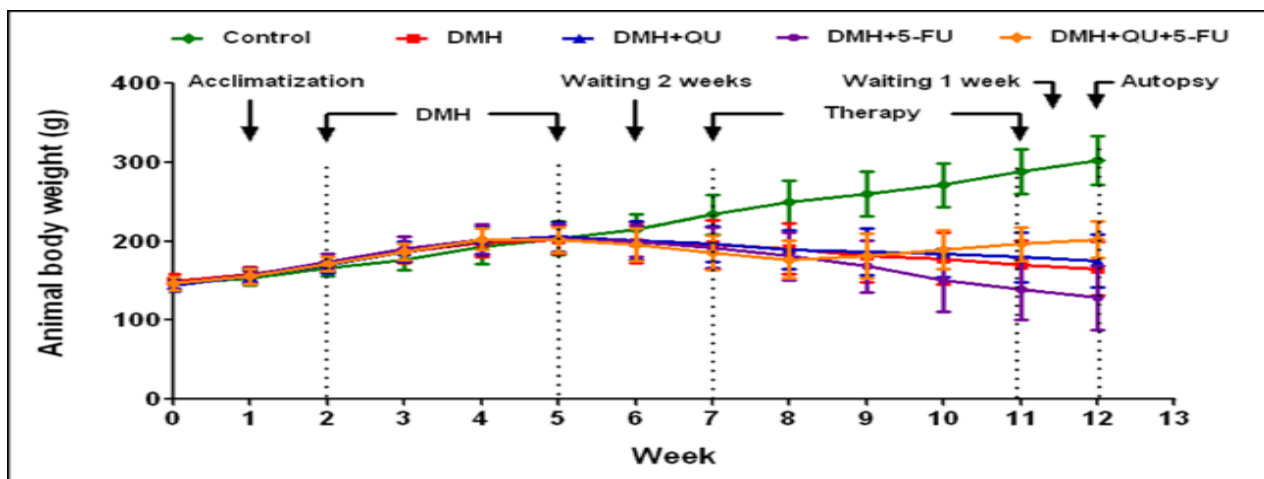
### Statistical analysis:

Statistical analyses of the data were carried out using Graphpad prism version 5.0 (Graphpad software San Diego, USA). Data comparisons were performed using analysis of variance (ANOVA) followed by Tukey's t-test. The levels of significance were accepted with  $p < 0.05$  and all relevant results were graphically displayed as mean  $\pm$  SD.

### Results:

#### Combination treatment with QU and 5-FU ameliorated weigh loss following DMH treatment:

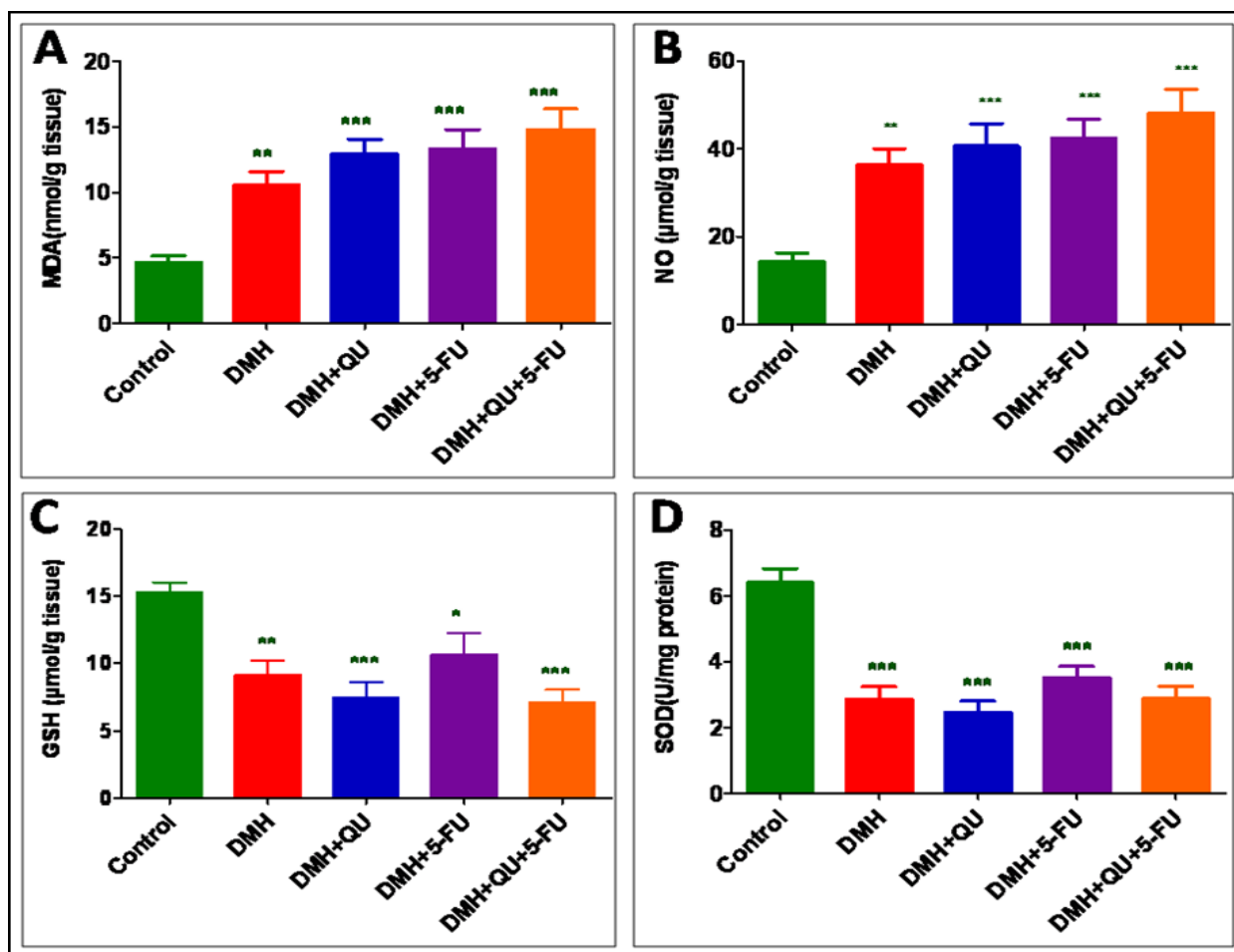
Animals in the healthy control group (no DMH injection) steadily gained significant body weight with  $\sim 106\%$  increase of the mean of their initial weights. This increase in the body weight gain was minimal in the DMH- and DMH+QU-treated animals which only gained  $\sim 10.5\%$  and  $\sim 21.7\%$  of their initial weights, respectively. Animals in the DMH+5-FU group were lethargic and lost  $\sim 12.5\%$  of the mean of their initial body weights. This weight loss was ameliorated following combining 5-FU with QU in the DMH+QU+5-FU group which showed  $\sim 38.3\%$  increase in the mean of their initial body weights. A summary of these results is shown in Figure 1.



**Figure 1:** Development of animal body weight in different groups. Data are presented as mean  $\pm$  SD. DMH, 1,2-dimethylhydrazine; QU, Quercetin; 5-FU, 5-fluorouracil.

Two deaths were recorded in the DMH group on days 50 and 73, i.e., the 36th and the 59th days after starting DMH injection. In (DMH+QU) group, only one animal died on day 65, i.e., the 51st day after starting DMH injection. In (DMH+5-FU) group, two deaths were recorded on

day 64 and 80, i.e. the 50<sup>th</sup> and the 66<sup>th</sup> day after starting DMH injection. Alternatively, no mortality was recorded among the animals of the healthy control and the combination (DMH+QU+5-FU) groups.



**Figure 2:** Levels of MDA (A), NO (B), GSH (C) and SOD (D) as markers of oxidative stress in colon tissue homogenates of different groups. Data are presented as mean ± SD. \*, †, ‡, and § indicate significant differences from control, DMH, DMH+QU and DMH+5-FU groups respectively. \*, †, ‡, and § indicate significant differences at  $p < 0.05$ ; \*\*, ††, ‡‡, and §§ indicate significant differences at  $p < 0.01$ ; \*\*\*, †††, ‡‡‡, and §§§ indicate significant differences at  $p < 0.001$ . GSH, Reduced glutathione; MDA, Malondialdehyde; NO, Nitric oxide; SOD, Superoxide dismutase; DMH, 1,2-dimethylhydrazine; QU, Quercetin; 5-FU, 5-fluorouracil.

**Administration of DMH was associated with increased levels of MDA and NO and decreased levels of GSH and SOD**

As compared to the healthy control group, colonic tissue contents of MDA and NO were significantly increased in (DMH) group ( $p < 0.01$  and  $p < 0.01$ , respectively), (DMH+QU) group ( $p < 0.001$  and  $p < 0.001$ , respectively), (DMH+5-FU) group ( $p < 0.001$  and  $p < 0.001$ , respectively), and (DMH+QU+5-FU) group ( $p < 0.001$  and  $p < 0.001$ , respectively). Conversely, the GSH content and SOD activity were significantly diminished in the colon tissues of all DMH-treated animals, i.e., (DMH) group ( $p < 0.01$  and  $p < 0.001$ , respectively),

(DMH+QU) group ( $p < 0.001$  and  $p < 0.001$ , respectively), (DMH+5-FU) group ( $p < 0.05$  and  $p < 0.001$ , respectively), and (DMH+QU+5-FU) group ( $p < 0.001$  and  $p < 0.001$ , respectively). It was also observed that neither individual nor combined therapy was able to significantly alter the tissue levels of any of the markers of oxidative stress in comparison to the (DMH) group. A summary of these results is shown in Figure 2.

**Combination treatment with QU and 5-FU ameliorated DMH-induced hyperplastic and dysplastic crypt abnormalities**

Administration of DMH induced hyperplastic and dysplastic crypt foci (preneoplastic lesions during



colorectal carcinogenesis). On histology, the hyperplastic ACF were characterized by elevated luminal openings, elongated crypts lined by slightly higher epithelium with nuclei at the base of cells. The dysplastic crypt foci were composed of colonic crypts lined by epithelial cells with stratified, hyperchromatic nuclei, loss of cell polarity and mucin depletion. The surrounding colonic tissue show areas of mucosal ulceration, expansion of the lamina propria by mixed inflammatory cell infiltrate with lymphoid follicle formation (indicative of chronic inflammatory response). The intake of DMH (DMH group) resulted in adverse histological changes and most of the animals (five animals) developed dysplastic ACF and (two animals) developed hyperplastic ACF. The injection of 5-FU (DMH+5-FU group) was associated with the development of both hyperplastic and dysplastic ACF (3 animals, each). The administration of QU (DMH+QU group) was associated with marked amelioration of the adverse histological changes, i.e., most of the animals developed hyperplastic ACF. Dysplastic ACF were completely absent in the colonic tissue of the animals receiving combination treatment (DMH+QU+5-FU) group. A summary of these results is presented in Figure 3 and Table 2.

***Combination treatment with QU and 5-FU was associated with decreased serum levels of CA19-9***

As compared to the healthy control group, serum levels of CA19-9 were significantly high in (DMH) group ( $p < 0.001$ ), (DMH+QU) group ( $p < 0.001$ ), (DMH+5-FU) group ( $p < 0.001$ ), and (DMH+QU+5-FU) group ( $p < 0.05$ ). As compared to (DMH) group, 5-FU alone (DMH+5-FU) and in combination with QU (DMH+QU+5-FU) was

associated with a significant reduction in the serum CA19-9 levels ( $p < 0.01$  and  $p < 0.001$ , respectively). As compared to treatment with single agent (DMH+QU or DMH+5-FU groups), treatment with combined regimen (DMH+QU+5-FU) was associated with a significant reduction in the serum CA19-9 levels ( $p < 0.001$  and  $p < 0.05$ , respectively). Noteworthy, treatment with 5-FU alone (DMH+5-FU) was not significantly superior over treatment with QU alone in (DMH+QU) group regarding the reduction of CA19-9 serum levels. A summary of these results is shown in Figure 4.

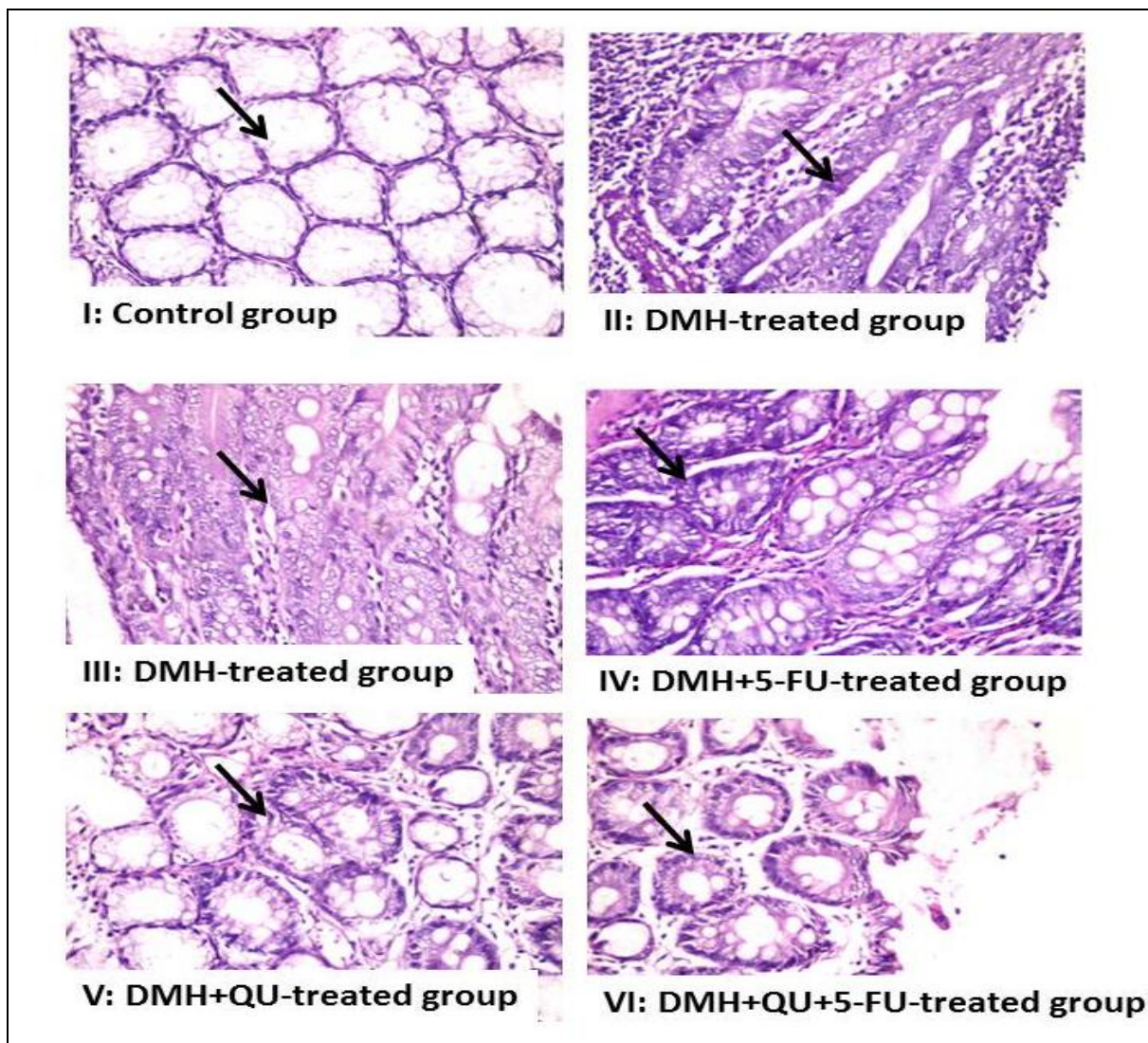
***Combination treatment with QU and 5-FU was associated with down-regulation of CDH12 protein***

As compared to healthy control group, there was a noteworthy over-expression of CDH12 protein in all DMH-treated animals, (DMH; DMH+QU, DMH+5-FU and DMH+QU+5-FU groups). Only, the combined QU and 5-FU treatment (DMH+QU+5-FU group) was associated with a decreased expression of CDH12 protein. A summary of these findings is shown in Figure 5A.

***Combination treatment with QU and 5-FU was associated with upregulation of SOX7 mRNA***

RT-PCR gel analysis showed a pronounced decrease in SOX7 mRNA levels in DMH-treated animals as compared to the healthy control group. In DMH+QU and DMH+5-FU treated animals, SOX7 gene expression was partially increased. In contrast, combined treatment with QU and 5-FU restored SOX7 to levels comparable with those of the normal healthy controls. A summary of these result are shown in Figure 5B.



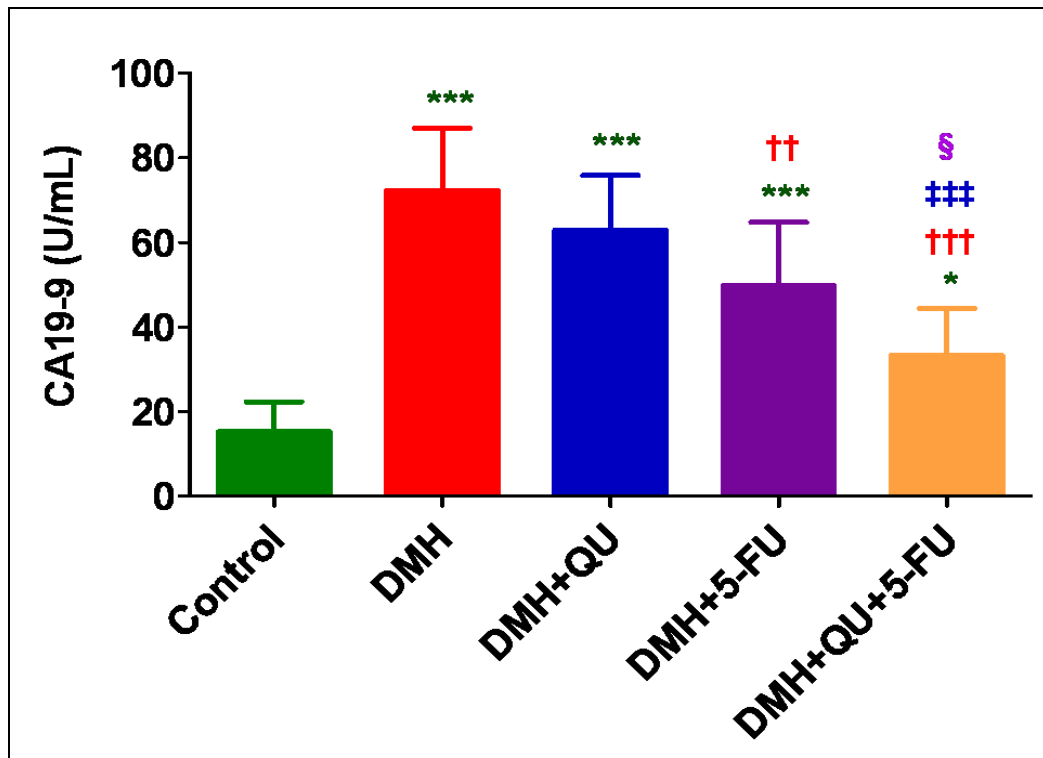


**Figure 3:** Histological changes in colonic tissues. I: Unremarkable mucosa of the control group with normal crypts (arrow); II-III: Dysplastic aberrant crypt foci in the DMH-treated animals. The crypts (arrows) show both architectural (elongated, distorted and crowded crypts) and cytological (nuclear crowding, nucleomegally, pleomorphism, hyperchromatism, vesicular nuclei and conspicuous nuclei with mucin depletion) features of dysplasia; IV: Hyperplastic aberrant crypt foci (arrow) in DMH+5-FU treated animals. The crypts show some cytological abnormalities including nuclear crowding, hyperchromasia and partial loss of mucin. V: Reversal of the histological alterations in the colonic mucosa of the animals receiving QU therapy (DMH+QU). The crypts (arrow) show subtle nuclear crowding and hyperchromasia. VI: Reversal of the histological alterations in the colonic mucosa of the animals receiving combined therapy (DMH+QU+5-FU). The crypts (arrow) lack features of architectural or cytological abnormalities indicative of ACF.


**Table 2:** Histological changes in the colonic mucosa of the rats following the administration of DMH

Group	Animals with ACF/Total number of animals	Type of ACF	
		Hyperplastic ACF	Dysplastic ACF
Control	0/10	0	0
DMH	7/8	2	5
DMH+5-FU	6/8	3	3
DMH+QU	8/9	5	3
DMH+QU+5-FU	2/10	2	0

The intake of DMH was associated with the development of dysplastic ACF. The intake of a single agent (either 5-FU or QU) was associated with decreasing numbers of dysplastic ACF. The latter were completely absent following the combination treatment (DMH+QU+5-FU). DMH, 1,2-dimethylhydrazine; QU, Quercetin; 5-FU, 5-fluorouracil.



**Figure 4:** Serum levels of CA19-9 in different groups. Data are presented as mean ± SD. \*, †, ‡, and § indicate significant differences from control, DMH, DMH+QU, and DMH+5-FU groups respectively. \*, †, ‡, and § indicate significant differences at p<0.05; \*\*, ††, ‡‡, and §§ indicate significant differences at p<0.01; \*\*\*, †††, ‡‡‡, and §§§ indicate significant differences at p<0.001. DMH, 1,2-dimethylhydrazine; QU, Quercetin; 5-FU, 5-fluorouracil.



**Figure 5:** Representative Western blotting analysis of CDH12 (A) and RT-PCR detection of SOX7 mRNA fragments (B) in colon tissue homogenates of different groups.  $\beta$ -actin was used in parallel as an internal control. The right panels represent corresponding quantification of each analysis measured by Image J software and expressed as a  $\beta$ -actin ratio. DMH, 1,2-dimethylhydrazine; QU, Quercetin, 5-FU, 5-fluorouracil.

**Discussion:**

CRC is one of the leading causes of cancer deaths worldwide. It occurs predominantly from accumulation of genetic and epigenetic changes in colon epithelial cells, which later gets transformed into adenocarcinomas. Identification of a new and safe combination for treatment of CRC opens up promising new targets in therapeutic intervention strategies [30].

QU has anticancer potential through promotion of apoptosis, inhibition of cell proliferation and angiogenesis [18, 31]. Combination of QU and various chemotherapeutics can improve the therapeutic efficacy of the latter by reducing drug resistance and by acting as a chemosensitizer compound [16, 32].

In support, the combination treatment of QU and doxorubicin provided an effective therapeutic regimen in breast cancer [16]. Also, in 1,2-dimethylhydrazin- induced colon cancer model, combination of quercetin and cisplatin ameliorates cisplatin-induced nephrotoxicity [33]. Moreover, quercetin induces apoptosis, suppression of metastatic ability, in human colon cancer, HCT-116 cells [34, 35, 36].

In the light of this knowledge, we evaluated the potential value of QU to improve the efficacy of 5-FU against DMH-induced adverse histological and molecular changes in the colon of Wistar rats. Our investigation clearly demonstrated that the intake of DMH is associated with adverse histological (development of ACF) and biochemical changes (elevated serum levels of CA19-9; reduced tissue levels of enzymatic antioxidants; elevated CDH12 protein expression and decreased SOX7 mRNA

levels). Importantly, our work provides the first indication that treatment of DMH-treated animals with QU+5-FU (but not with QU or 5-FU as a single agent therapy) significantly reversed these changes (i.e., inhibited the formation of ACF; decreased the serum of CA19-9 levels; reduced CDH12 protein expression and increased SOX7 mRNA expression). To the best of our knowledge, the current work was the first to address the molecular alterations of CDH12 and SOX7 (promising biomarkers in CRC) in DMH-treated rat colon.

***Combination treatment with QU and 5-FU ameliorated weigh loss following DMH treatment***

Weight loss is a common complication of the gastrointestinal neoplasms [37]. In agreement with other reports, we found that DMH-injected animals failed to gain weight whereas the healthy control group gained significant weights [38]. The DMH-induced failure to gain weight is reasoned to decreased food intake secondary to neoplastic transformation [39], together with altered glucose metabolism with increased hepatic gluconeogenesis depleting the energy sources [22]. The weight loss observed in the 5-FU treated group (DMH+5-FU), is possibly due to 5-FU induced mucositis which occurs in ~60% of cancer patients receiving this drug [40]. In contrast, DMH-induced failure to gain weight was significantly ameliorated in animals receiving combination treatment (DMH+QU+5-FU). This is probably due to the ability QU to prevent 5-FU-induced mucositis through its antiinflammatory, antioxidant effects [41] and its potential to promote wound healing [42].

***Combination treatment with QU and 5-FU was associated with decreased serum levels of CA19-9***

In agreement with other studies, we found a significantly increased serum levels of CA19-9 following DMH injection as compared to the healthy control group [14]. This is probably due to the inflammation associated colonic tissue damage secondary to the release of the reactive oxygen radicals [43]. Also, elevated preoperative serum CA 19-9 level may be useful in predicting peritoneal metastasis in colorectal cancer [44, 45].

Alternatively, combined administration of QU and 5-FU (DMH+QU+5-FU) resulted in a significant decrease in the serum CA19-9 levels as compared to single agent therapy (DMH+QU or DMH+5-FU) possibly due to the antiproliferative properties of QU and to its combined effects together with 5-FU [14].

***Combination treatment with QU and 5-FU was associated with down-regulation of CDH2 protein***

The upregulation of CDH12 protein following DMH administration with the development of ACF is consistent with the fact that CDH12 promotes proliferation and tumorigenesis [46, 47]. This CDH12 upregulation may be reasoned to the role of oxidative stress in the disruption of intercellular adhesion (E-cadherin/catenin cell adhesion complex) [48]. The down-regulation of CDH12 protein following combination treatment with QU and 5-FU (DMH+QU+5-FU group) as compared to animals treated with single agent (DMH+QU or DMH+5-FU) suggests beneficial antiproliferative roles for QU. Zhao et al examined the expression levels of CDH12 in CRC patients using immunohistochemical staining methods (tumor tissues), Real-time PCR and Western Blot (cell lines). CDH12 protein expression was high in tumor tissue as compared to the adjacent non-

neoplastic one. The decreased levels of CDH12 were associated with suppressed ability of proliferation, migration and invasion of the tumor cells. In addition, the down-regulation of CDH12 was associated with inhibition of angiogenesis indicating the angiogenetic roles of CDH12 [46]. Taken as a whole, CDH12 seems to act as an oncogene during CRC tumorigenesis.

***Combination treatment with QU and 5-FU was associated with up-regulation of SOX7 mRNA***

In the current study, RT-PCR gel analysis showed decreased SOX7 mRNA levels in DMH-treated animals compared to the healthy control group. This finding concurs with previous studies which demonstrated SOX7 down-regulation in CRC [49] as well as in breast, prostate, kidney, lung and pancreatic cancer tissues [50, 51, 52, 53]. In CRC cell lines, SOX7 silencing was reasoned to SOX7 gene methylation. Restoration of SOX7 activity was associated with enhanced apoptosis in the cancer cells and inhibition of their proliferation. The upregulation of SOX7 expression following combination treatment (DMH+QU+5-FU) with lack of ACF supports its antiproliferative activities. In support, SOX7 over-expression suppressed cell proliferation and colony formation in prostate and CRC cell lines and induced apoptosis in CRC cells [49, 50]. Moreover, SOX7 upregulation inhibits proliferation, migration, and invasion of breast cancer cells *in vitro* and tumor growth *in vivo* [54]. Taken together, SOX7 acts as a tumor suppressor and has a great potential to serve as a prognostic marker for cancer patients [54].

***Combination treatment with QU and 5-FU suppressed the development of DMH-induced aberrant crypt foci***

In agreement with other groups we observed the development of crypt hyperplastic and dysplastic changes (ACF) in DMH-treated animals [55]. The DMH-induced ACF are related to chronic inflammation with the induction of severe oxidative stress (with increase in MDA, decrease in GSH). DMH intake can increase inducible nitric synthase, nitrites level and arginase activity with development of nitrosative stress and cell proliferation [56]. The carcinogenic metabolites of DMH are responsible for modifying nucleic acids (DNA methylation), histones and other DNA-binding proteins. The ability of the combined QU+5-FU treatment to suppress the formation of ACF concurs with other studies [57, 58]

Several reports support our findings. Feeding rats with QU was associated with reduction in crypt cell mitosis. In DMH-treated animals, the intake of QU resulted in the suppression of mitosis; decrease the number of aberrant crypts and larger ACF [59]. Moreover, in animals treated with azoxymethane, QU supplementation reduced the number of ACF in animals fed with high-fat diet [60]. Using Sprague Dawley rat model, Turner et al indicated that the addition of a diet containing corn and cellulose suppressed the development of multiple ACF, inhibited proliferation and enhanced apoptosis (via the mitochondrial pathway) in a rat model of colon cancer. These effects were related to the antiinflammatory actions of QU and were mediated by its role in down-regulating COX-1 and COX-2 expression [58, 61]

***Administration of DMH was associated with increased levels of MDA and NO and decreased levels of GSH and SOD***

The balance between antioxidant and lipid peroxidation status is a useful tool in estimating the risk of oxidative damage-induced carcinogenesis [62]. In agreement with other groups [62, 63], signs of intense perturbations in the oxidant/antioxidant balance were clearly reported in our investigation which revealed serious increases in oxidative and nitrosative damage in colonic tissues of DMH-treated animals in the form of significant increases in the level of lipid peroxidation products (MDA and NO) associated concomitantly with significant decrease in the levels of antioxidants (GSH content and SOD activity) as compared to the healthy control group. DMH can induce oxidative metabolism resulting in the production of electrophilic diazonium ion, which evokes oxidative stress in the tissues leading to generation of harmful reactive oxygen species (ROS) such as superoxide anion radical, hydroxyl radical, and peroxy radical [64]. Nitric oxide is a free radical with short half-life, which has a variety of biological roles, including vasodilatation, stimulation of tumor growth and enhancement of T-cell response to immunogenic tumors [65]. Free radicals are regularly generated *in vivo* as a result of DMH treatment causing oxidative stress that causes damage to nucleic acid, proteins and lipids resulting in chromosomal instability, mutation, loss of organelle function and membrane damage which play a significant mechanistic role in the development of cancer [66]. In our study, individual 5-FU administration (DMH+5-FU group) potentiated the DMH-induced

oxidant/antioxidant disruption, probably due to the 5-FU-generated mitochondrial ROS in the p53-dependent pathway and 5-FU-derived ROS stress leads to tumor cell death [67].

***Administration of QU and 5-FU was associated with increased levels of MDA and NO and decreased levels of GSH and SOD***

In our series, the administration of QU (DMH+QU or DMH+5-FU+QU), was associated with insignificant increases in the colonic tissue levels of lipid peroxidation products (MDA and NO) with concomitant insignificant decreases in the levels of antioxidants (GSH content and SOD activity). This finding concurs with the fact that QU act not only as an antioxidant, but also as a cytotoxic prooxidant in rats [68]. In support, Choi and colleagues examined the outcome of chronic administration of QU on lipid peroxidation and glutathione concentration in Male Sprague-Dawley rat livers. The intake of QU was associated with decreased levels of the glutathione concentration and glutathione reductase activity in the liver [68]. The cytotoxic prooxidant capabilities of QU are related to its metabolic oxidoreductive activation [69]. Using ESR spin-stabilization technique coupled to conventional spectrophotometry, Metodiewa, et al indicated the intracellular metabolic activation of QU to o-semiquinone and o-quinone. The former promotes generation of superoxide and depletion of glutathione. The one-electron reduction of o-quinone can enrich the semiquinone pool and therefore magnify its cytotoxic prooxidant effects [69]. The cytotoxic prooxidant effects can induce apoptosis of the tumor cells and therefore may have potential beneficial chemotherapeutic effects.

The ability of QU+5-FU to ameliorate DMH-induced adverse histological and biochemical changes in the colon of Wistar rats is in agreement with other studies [16, 32]. The possible underlying mechanisms include the prooxidant properties of QU, and its effects on some important cell cycle molecules. In support, in p53-null cells, the combination of low dose of 5-FU with up to 6  $\mu$ M QU promoted clonogenic survival. Treatment of p53 wild-type cells with 50  $\mu$ M QU reduced drug-induced up-regulation of p53, p21 and BAX. The combination of QU and the drugs also reduced the levels of cyclin B1 and survivin proteins [70]. In invasive mammary carcinoma, the combined treatment with both QU and doxorubicin can increase the efficacy of doxorubicin. In non-neoplastic cells; QU reduced doxorubicin cytotoxic side effects. Taken together, QU combined with conventional antineoplastic agents demonstrated very promising properties for developing chemotherapeutics combinations [32].

Conclusively, the current findings indicate that the combined QU+5-FU treatment can attenuate 1, 2-dimethylhydrazine induced adverse histological and biochemical changes in the colon of Wistar rats. Further studies, including immunohistochemical evaluations, are needed to examine if other cadherin- or SOX-family proteins are also similarly modulated by QU+5-FU combination. Also, the clinical and therapeutic ramification of our data awaits further investigations.

**Financial Disclosure**

This research did not receive any specific grant from funding agencies in the public, commercial, or not-for-profit sectors.



### Declaration of Interest section

The authors report no declarations of interest.

### References

- [1]Tao, L., Yang, J. K., Gu, Y., Zhou, X., Zhao, A. G., Zheng, J., Zhu, Y. J.; Weichang'an and 5-fluorouracil suppresses colorectal cancer in a mouse model. *World J Gastroenterol* 21, 1125-1139, 2015.
- [2]Govatati, S., Singamsetty, G. K., Nallabelli, N., Malempati, S., Rao, P. S., Madamchetty, V. K., Govatati, S., Kanapuram, R., Narayana, N., Bhanoori, M., Kassetty, K., Nallanchakravarthula, V. :Contribution of cyclin D1 (CCND1) and E-cadherin (CDH1) alterations to colorectal cancer susceptibility: a case-control study. *Tumour Biol* 35, 12059-12067, 2014.
- [3]Nirmala, P., Ramanathan, M.: Effect of kaempferol on lipid peroxidation and antioxidant status in 1,2-dimethyl hydrazine induced colorectal carcinoma in rats. *Eur J Pharmacol* 654, 75-79, 2011.
- [4]Ramirez-Ramirez, M. A., Sobrino-Cossio, S., de la Mora-Levy, J. G., Hernandez-Guerrero, A., Macedo-Reyes Vde, J., Maldonado-Martinez, H. A., Alonso-Larraga, J. O., Ramirez-Solis, M. E.: Loss of expression of DNA mismatch repair proteins in aberrant crypt foci identified in vivo by magnifying colonoscopy in subjects with hereditary nonpolyposic and sporadic colon rectal cancer. *J Gastrointest Cancer* 43, 209-214, 2012.
- [5]Sisik, A., Kaya, M., Bas, G., Basak, F., Alimoglu, O.: CEA and CA 19-9 are still valuable markers for the prognosis of colorectal and gastric cancer patients. *Asian Pac J Cancer Prev* 14, 4289-4294, 2013.
- [6]Dong, H., Tang, J., Li, L. H., Ge, J., Chen, X., Ding, J., Men, H. T., Luo, W. X., Du, Y., Li, C.: Serum carbohydrate antigen 19-9 as an indicator of liver metastasis in colorectal carcinoma cases. *Asian Pacific Journal of Cancer Prevention* 14, 909-913, 2013.
- [7]Dong, W., Yu, Q., Xu, Y.: Altered expression of a Li-cadherin in gastric cancer and intestinal metaplasia. *Dig Dis Sci* 52, 536-542, 2007.
- [8]Alexander, N. R., Tran, N. L., Rekapally, H., Summers, C. E., Glackin, C., Heimark, R. L.: N-cadherin gene expression in prostate carcinoma is modulated by integrin-dependent nuclear translocation of Twist1. *Cancer research* 66, 3365-3369, 2006.
- [9]Li, K., He, W., Lin, N., Wang, X., Fan, Q. X.: Downregulation of N-cadherin expression inhibits invasiveness, arrests cell cycle and induces cell apoptosis in esophageal squamous cell carcinoma. *Cancer Invest* 28, 479-486, 2010.
- [10]Wang, J. F., She, L., Su, B. H., Ding, L. C., Zheng, F. F., Zheng, D. L., Lu, Y. G.: CDH12 promotes the invasion of salivary adenoid cystic carcinoma. *Oncol Rep* 26, 101-108, 2011.
- [11]Zhou, X., Huang, S. Y., Feng, J. X., Gao, Y. Y., Zhao, L., Lu, J., Huang, B. Q., Zhang, Y.: SOX7 is involved in aspirin-mediated growth inhibition of human colorectal cancer cells. *World journal of gastroenterology: WJG* 17, 4922, 2011.
- [12]Costa, G., Mazan, A., Gandillet, A., Pearson, S., Lacaud, G., Kouskoff, V.: SOX7 regulates the expression of VE-cadherin in the haemogenic

endothelium at the onset of haematopoietic development. *Development* 139, 1587-1598, 2012.

- [13]Srimuangwong, K., Tocharus, C., Tocharus, J., Suksamrarn, A., Chintana, P. Y.: Effects of hexahydrocurcumin in combination with 5-fluorouracil on dimethylhydrazine-induced colon cancer in rats. *World J Gastroenterol* 18, 6951-6959, 2012.
- [14]Muthu, R., Vaiyapuri, M.: Synergistic and individual effects of umbelliferone with 5-fluorouracil on tumor markers and antioxidant status of rat treated with 1, 2-dimethylhydrazine. *Biomedicine & Aging Pathology* 3, 219-227, 2013.
- [15]Dias, T. A., Duarte, C. L., Lima, C. F., Proenca, M. F., Pereira-Wilson, C.: Superior anticancer activity of halogenated chalcones and flavonols over the natural flavonol quercetin. *Eur J Med Chem* 65, 500-510, 2013.
- [16]Du, G., Lin, H., Yang, Y., Zhang, S., Wu, X., Wang, M., Ji, L., Lu, L., Yu, L., Han, G.: Dietary quercetin combining intratumoral doxorubicin injection synergistically induces rejection of established breast cancer in mice. *Int Immunopharmacol* 10, 819-826, 2010.
- [17]Pan, M. H., Lai, C. S., Wu, J. C., Ho, C. T.: Molecular mechanisms for chemoprevention of colorectal cancer by natural dietary compounds. *Mol Nutr Food Res* 55, 32-45, 2011.
- [18]Gupta, C., Vikram, A., Tripathi, D. N., Ramarao, P., Jena, G. B.: Antioxidant and antimutagenic effect of quercetin against DEN induced hepatotoxicity in rat. *Phytother Res* 24, 119-128, 2010.
- [19]Kim, H. J., Kim, S. K., Kim, B. S., Lee, S. H., Park, Y. S., Park, B. K., Kim, S. J., Kim, J., Choi, C., Kim, J. S., Cho, S. D., Jung, J. W., Roh, K. H., Kang, K. S., Jung, J. Y.: Apoptotic effect of quercetin on HT-29 colon cancer cells via the AMPK signaling pathway. *J Agric Food Chem* 58, 8643-8650, 2010.
- [20]Park, C. H., Chang, J. Y., Hahm, E. R., Park, S., Kim, H. K., Yang, C. H.: Quercetin, a potent inhibitor against beta-catenin/Tcf signaling in SW480 colon cancer cells. *Biochem Biophys Res Commun* 328, 227-234, 2005.
- [21]Heeba, G. H., Mahmoud, M. E.: Dual effects of quercetin in doxorubicin-induced nephrotoxicity in rats and its modulation of the cytotoxic activity of doxorubicin on human carcinoma cells. *Environ Toxicol*, 10.1002/tox.22075, 2014.
- [22]Karthikkumar, V., Sivagami, G., Vinothkumar, R., Rajkumar, D., Nalini, N.: Modulatory efficacy of rosmarinic acid on premalignant lesions and antioxidant status in 1,2-dimethylhydrazine induced rat colon carcinogenesis. *Environ Toxicol Pharmacol* 34, 949-958, 2012.
- [23]Banchroft, J. D., Stevens, A., Turner, D. R.: Theory And Practice Of Histological Techniques, fourth ed. ed., New York, London, San Francisco, Tokyo: Churchill Livingstone, 1996.
- [24]Bird, R. P., Good, C. K.: The significance of aberrant crypt foci in understanding the pathogenesis of colon cancer. *Toxicol Lett* 112-113, 395-402, 2000.
- [25]Cheng, L., Lai, M. D.: Aberrant crypt foci as microscopic precursors of colorectal cancer. *World J Gastroenterol* 9, 2642-2649, 2003.

- [26]Mihara, M., Uchiyama, M.: Determination of malonaldehyde precursor in tissues by thiobarbituric acid test. *Anal Biochem* 86, 271-278, 1978.
- [27]Ellman, G. L.: Tissue sulfhydryl groups. *Arch Biochem Biophys* 82, 70-77, 1959.
- [28]Marklund, S., Marklund, G.: Involvement of the superoxide anion radical in the autoxidation of pyrogallol and a convenient assay for superoxide dismutase. *Eur J Biochem* 47, 469-474, 1974.
- [29]Sessa, W. C., Pritchard, K., Seyedi, N., Wang, J., Hintze, T. H.: Chronic exercise in dogs increases coronary vascular nitric oxide production and endothelial cell nitric oxide synthase gene expression. *Circ Res* 74, 349-353, 1994
- [30] Das, V., Kalita, J., Pal, M.: Predictive and prognostic biomarkers in colorectal cancer: A systematic review of recent advances and challenges. *Biomed Pharmacother* 87, 8-19, 2017.
- [31]Ishikawa, Y., Kitamura, M.: Anti-apoptotic effect of quercetin: intervention in the JNK- and ERK-mediated apoptotic pathways. *Kidney Int* 58, 1078-1087, 2000
- [32]Staedler, D., Idrizi, E., Kenzaoui, B. H., Juillerat-Jeanneret, L.: Drug combinations with quercetin: doxorubicin plus quercetin in human breast cancer cells. *Cancer Chemother Pharmacol* 68, 1161-1172, 2011.
- [33] Li, Q.C., Liang, Y., Hu, G.R., Tian, Y.: Enhanced therapeutic efficacy and amelioration of cisplatin-induced nephrotoxicity by quercetin in 1,2-dimethylhydrazin-induced colon cancer in rats. *Indian J Pharmacol* 48(2), 168-171, 2016.
- [34] Khan, I., Paul, S., Jakhar, R., Bhardwaj, M., Han, J., Kang S.C.: Novel quercetin derivative TEF induces ER stress and mitochondria-mediated apoptosis in human colon cancer HCT-116 cells. *Biomed Pharmacother* 84, 789-799, 2016.
- [35] Kee, J.Y., Han, Y.H., Kim, D.S., Mun, J.G., Park, J., Jeong, M.Y., Um, J.Y., Hong, S.H.: Inhibitory effect of quercetin on colorectal lung metastasis through inducing apoptosis and suppression of metastatic ability. *Phytomedicine* 23(13), 1680-1690, 2016.
- [36] Saleem, T.H., Attya, A.M., Ahmed, E.A., Ragab, S.M., Ali Abdallah, M.A., Omar, H.M.: Possible protective effects of quercetin and sodium gluconate against colon cancer induction by dimethylhydrazine in mice. *Asian Pac Cancer Prev* 16(14), 5823-5828, 2016.
- [37]Andrejev, H. J. N., Norman, A. R., Oates, J., Cunningham, D.: Why do patients with weight loss have a worse outcome when undergoing chemotherapy for gastrointestinal malignancies? *European Journal of Cancer* 34, 503-509, 1998.
- [38]Sakamoto, S., Mori, T., Sawaki, K., Kawachi, Y., Kuwa, K., Kudo, H., Suzuki, S., Sugiura, Y., Kasahara, N., Nagasawa, H.: Effects of kampo (Japanese herbal) medicine "sho-saiko-to" on DNA-synthesizing enzyme activity in 1,2-dimethylhydrazine-induced colonic carcinomas in rats. *Planta Med* 59, 152-154, 1993.
- [39]Gold, J.: Cancer cachexia and gluconeogenesis. *Ann N Y Acad Sci* 230, 103-110, 1974.
- [40]Whittaker, A. L., Lymn, K. A., Nicholson, A., Howarth, G. S.: The assessment of general well-being using spontaneous burrowing behaviour

in a short-term model of chemotherapy-induced mucositis in the rat. *Lab Anim* 49, 30-39, 2015.

- [41]Yarom, N., Ariyawardana, A., Hovan, A., Barasch, A., Jarvis, V., Jensen, S. B., Zadik, Y., Elad, S., Bowen, J., Lalla, R. V., Mucositis Study Group of the Multinational Association of Supportive Care in Cancer/International Society of Oral, O.: Systematic review of natural agents for the management of oral mucositis in cancer patients. *Support Care Cancer* 21, 3209-3221, 2013.
- [42]Jangde, R., Singh, D.: Preparation and optimization of quercetin-loaded liposomes for wound healing, using response surface methodology. *Artif Cells Nanomed Biotechnol* 44, 635-641, 2016.
- [43]Wiwanitkit, V.: CA 19-9, PSA, oxidative stress and chronic pancreatitis. *Clinical biochemistry* 45, 512, 2012
- [44]Kaneke, M., Ishihara, S., Muroto, K., Sasaki, K., Otani, K., Yasuda, K., Nishikawa, T., Tanaka, T., Kiyomatsu, T., Hata, K., Kawai, K., Nozawa, H., Nakayama, H., Watanabe, T., Sasaki, S., Watanabe, T.: Carbohydrate antigen 19-9 predict synchronous peritoneal carcinomatosis in patients with colorectal cancer. *Anticancer*, 37(2), 865-870, 2017.
- [45]Stojkovic Lalosevic, M., Stankovic, S., Stojkovic, M., Markovic, V., Dimitrijevic, I., Lalosevic, J., Petrovic, J., Brankovic, M., Pavlovic Markovic, A., Krivokapic, Z.: Can preoperative CEA and CA 19-9 serum concentrations suggest metastatic disease in colorectal cancer patients? *Hell J Nucl Med*, 20(1), 41-45, 2017.
- [46]Zhao, J., Li, P., Feng, H., Wang, P., Zong, Y., Ma, J., Zhang, Z., Chen, X., Zheng, M., Zhu, Z., Lu, A.: Cadherin-12 contributes to tumorigenicity in colorectal cancer by promoting migration, invasion, adhesion and angiogenesis. *J Transl Med* 11, 288, 2013.
- [47] Chung, Y.C., Wei, W.C., Hung, C.N., Kuo, J.F., Hsu C.P., Chang, K.J., Chao, W.T.: Rab11 collaborates E-cadherin to promote collective cell migration and indicates a poor prognosis in colorectal carcinoma. *Eur J Clin Invest*, 46(12), 1002-1011, 2016.
- [48]Schmelz, M., Schmid, V. J., Parrish, A. R.: Selective disruption of cadherin/catenin complexes by oxidative stress in precision-cut mouse liver slices. *Toxicological sciences : an official journal of the Society of Toxicology* 61, 389-394, 2001.
- [49]Zhang, Y., Huang, S., Dong, W., Li, L., Feng, Y., Pan, L., Han, Z., Wang, X., Ren, G., Su, D., Huang, B., Lu, J.: SOX7, down-regulated in colorectal cancer, induces apoptosis and inhibits proliferation of colorectal cancer cells. *Cancer Lett* 277, 29-37, 2009.
- [50]Guo, L., Zhong, D., Lau, S., Liu, X., Dong, X. Y., Sun, X., Yang, V. W., Vertino, P. M., Moreno, C. S., Varma, V.: Sox7 is an independent checkpoint for  $\beta$ -catenin function in prostate and colon epithelial cells. *Molecular Cancer Research* 6, 1421-1430, 2008.
- [51]Kato, M.: Expression of human SOX7 in normal tissues and tumors. *Int J Mol Med* 9, 363-368, 2002.
- [52] Wang, J., Zhang, S., Wu, J., Lu, Z., Yang, J., Wu, H., Chen, H., Lin, B., Cao, T.: Clinical significance and prognostic value of SOX7

expression in liver and pancreatic carcinoma. *Mol Med Rep* 16(1), 499-506, 2017.

[53] **Bao, Y., Chen, B., Wu, Q., Hu, K., Xi, X., Zhu, W., Zhong, X., Chen, J.:** Overexpression of miR-664 is associated with enhanced osteosarcoma cell migration and invasion ability via targeting SOX7. *Clin Exp Med* 17(1), 51-58, 2017.

[54] **Stovall, D. B., Wan, M., Miller, L. D., Cao, P., Maglic, D., Zhang, Q., Stampfer, M. R., Liu, W., Xu, J., Sui, G.:** The regulation of SOX7 and its tumor suppressive role in breast cancer. *Am J Pathol* 183, 1645-1653, 2013.

[55] **Sivagami, G., Karthikkumar, V., Balasubramanian, T., Nalini, N.:** The modulatory influence of p-methoxycinnamic acid, an active rice bran phenolic acid, against 1,2-dimethylhydrazine-induced lipid peroxidation, antioxidant status and aberrant crypt foci in rat colon carcinogenesis. *Chem Biol Interact* 196, 11-22, 2012.

[56] **Bounaama, A., Djerdjouri, B., Laroche-Clary, A., Le Morvan, V., Robert, J.:** Short curcumin treatment modulates oxidative stress, arginase activity, aberrant crypt foci, and TGF-beta1 and HES-1 transcripts in 1,2-dimethylhydrazine-colon carcinogenesis in mice. *Toxicology* 302, 308-317, 2012.

[57] **Tanaka, T., Kawabata, K., Honjo, S., Kohno, H., Murakami, M., Shimada, R., Matsunaga, K., Yamada, Y., Shimizu, M.:** Inhibition of azoxymethane-induced aberrant crypt foci in rats by natural compounds, caffeine, quercetin and morin. *Oncol Rep* 6, 1333-1340, 1999.

[58] **Volate, S. R., Davenport, D. M., Muga, S. J., Wargovich, M. J.:** Modulation of aberrant crypt

foci and apoptosis by dietary herbal supplements (quercetin, curcumin, silymarin, ginseng and rutin). *Carcinogenesis* 26, 1450-1456, 2005.

[59] **Gee, J. M., Hara, H., Johnson, I. T.:** Suppression of intestinal crypt cell proliferation and aberrant crypt foci by dietary quercetin in rats. *Nutrition and cancer* 43, 193-201, 2002.

[60] **Choi, S. Y., Park, J. H., Kim, J. S., Kim, M. K., Aruoma, O. I., Sung, M. K.:** Effects of quercetin and beta-carotene supplementation on azoxymethane-induced colon carcinogenesis and inflammatory responses in rats fed with high-fat diet rich in omega-6 fatty acids. *BioFactors* 27, 137-146, 2006.

[61] **Turner, N. D., Paulhill, K. J., Warren, C. A., Davidson, L. A., Chapkin, R. S., Lupton, J. R., Carroll, R. J., Wang, N.:** Quercetin Suppresses Early Colon Carcinogenesis Partly through Inhibition of Inflammatory Mediators. *Acta Horti* 841, 237-242, 2009.

[62] **Khan, R., Sultana, S.:** Farnesol attenuates 1,2-dimethylhydrazine induced oxidative stress, inflammation and apoptotic responses in the colon of Wistar rats. *Chem Biol Interact* 192, 193-200, 2011.

[63] **Devasena, T., Menon, V. P., Rajasekharan, K. N.:** Prevention of 1,2-dimethylhydrazine-induced circulatory oxidative stress by bis-1,7-(2-hydroxyphenyl)-hepta-1,6-diene-3,5-dione during colon carcinogenesis. *Pharmacological reports : PR* 58, 229-235, 2006.

[64] **Harzallah, H. J., Neffati, A., Skandrani, I., Maaloul, E., Chekir-Ghedira, L., Mahjoub, T.:** Antioxidant and antigenotoxic activities of

Globularia alypum leaves extracts. *Journal of Medicinal Plant Research* 4, 2048-2053, 2010.

[65]Filippou, D., Papadopoulos, V. P., Triga, A., Filippou, G., Rizos, S., Skandalakis, P., Manolis, E.: Nitric oxide, antioxidant capacity, nitric oxide synthase and xanthine oxidase plasma levels in a cohort of burn patients. *Burns* 33, 1001-1007, 2007.

[66]Waris, G., Ahsan, H.: **Reactive oxygen species:** role in the development of cancer and various chronic conditions. *J Carcinog* 5, 14, 2006.

[67]Hwang, I. T., Chung, Y. M., Kim, J. J., Chung, J. S., Kim, B. S., Kim, H. J., Kim, J. S., Yoo, Y. D.: Drug resistance to 5-FU linked to reactive oxygen species modulator 1. *Biochem Biophys Res Commun* 359, 304-310, 2007.

[68]Choi, E. J., Chee, K. M., Lee, B. H.: Anti- and prooxidant effects of chronic quercetin administration in rats. *Eur J Pharmacol* 482, 281-285, 2003.

[69]Metodieva, D., Jaiswal, A. K., Cenas, N., Dickancaite, E., Segura-Aguilar, J.: Quercetin may act as a cytotoxic prooxidant after its metabolic activation to semiquinone and quinoidal product. *Free radical biology & medicine* 26, 107-116, 1999.

[70]Samuel, T., Fadlalla, K., Mosley, L., Katkoori, V., Turner, T., Manne, U.: Dual-mode interaction between quercetin and DNA-damaging drugs in cancer cells. *Anticancer research* 32, 61-71, 2012.